



Research Article

Acute Oral Toxicity, Haematobiochemical Parameters and Histopathological Evaluation of Povidone Iodine in Mice

Mohammad Kamal Ibrahim¹, Dahiru Sani^{1*} and Sarah Princess Edoh²

¹Department of Pharmacology and Toxicology, Faculty of Veterinary Medicine, Ahmadu Bello University Zaria, Kaduna State, 810006, Nigeria

²Department of Zoology, Faculty of Life Sciences, Ahmadu Bello University Zaria, Kaduna State, 810006, Nigeria

*Corresponding author: Email: mdsani77@gmail.com, doi.org/10.55639/607.898887

ARTICLE INFO:

Keyword:

Acute oral toxicity,
Povidone Iodine,
Histopathology,
Mice

ABSTRACT

Povidone-iodine is a synthetically produced topical antiseptic with a broad antimicrobial spectrum indicated for both treatment and prevention. Povidone-iodine (a synthetic povidone-iodine solution) however, is being used by poultry farmers and some animal health practitioners with claims that it is effective against infectious bursal disease (IBD) when administered orally. And recently, research studies have shown that povidone-iodine mouthwashes, throat sprays, nasal sprays and eye drops prevent the replication and or viral loads of SARS-CoV-2. Thus, this study established a safety profile of povidone-iodine. Ten adult mice were randomly assigned into 2 groups, each containing 5 mice. One of the two groups was treated with povidone-iodine orally, at a limit dose of 2,000mg/kg BW while the other group served as normal control. At the end of the study, blood samples were collected for hematological and biochemical analysis. Also, liver and kidney were harvested for both gross and histopathological examinations. Result showed the median lethal dose (LD₅₀) of povidone-iodine was found to be >2,000mg/kg BW. Significant increase ($p < 0.05$) of total white blood cells, monocytopenia and increased band cells were observed in the treated group when compared to the control on haematology. However, serum biochemistry revealed significant increase ($p < 0.01$) of Aspartate aminotransferase, Alanine aminotransferase, alkaline phosphatase and Blood urea nitrogen. On histopathology, no remarkable changes in the group treated with povidone iodine were observed when compared to the control. In conclusion, this study has showed the relative safety of povidone iodine at limit dose (2,000 mg/kg BW) in mice.

Corresponding author: Dahiru Sani, Email: mdsani77@gmail.com

Department of Veterinary Pharmacology and Toxicology, Ahmadu Bello University, Zaria

INTRODUCTION

Povidone-iodine (PI) is a synthetically produced topical antiseptic with a broad antimicrobial spectrum indicated for both treatment and prevention. It has widely been used preoperatively as a surgical scrub for skin cleansing, and for the treatment of infected wounds and burns. (Ripa *et al.*, 2002). Povidone-iodine has proven active against many enveloped and non-enveloped viruses (Kawana *et al.*, 1997); fungi and protozoans (Jean-Marie *et al.*, 2013). Polidine® however, is being used by poultry farmers and some animal health practitioners with claims that it is effective against infectious bursal disease (IBD) when administered orally (Aliyu *et al.*, 2016). And recently, research studies have shown that Povidone mouthwashes, throat sprays, nasal sprays and eye drops prevent the replication and or viral loads of SARS-CoV-2 (Bidra *et al.*, 2020). As an anciently known antimicrobial agent, the iodine component is a weak solution that releases free iodine. Its complex with non-ionic surfactants - known as iodophors (Aliu, 2007), kills even bacterial spores within a very short time. Iodophores therefore, are iodine-releasing agents resulting from the combination of iodine with a solubilizing agent in aqueous solutions since iodine by itself is water insoluble. Povidone-iodine for example, has been used on skin and tissues against a wide range of bacteria as an antiseptic (Wood and Payne 1998; Kariwa *et al.*, 2006; Eggers *et al.*, 2018). Being a small molecule, iodine rapidly penetrates into microorganisms and act by oxidizing vital proteins, nucleotides, and fatty acids, which eventually leads to cell death (Jean-Marie *et al.*, 2013). Povidone-iodine is extensively used both intra- and post-operatively to promote antisepsis through wound irrigation. Although 10% povidone-iodine is the standard for pre-surgical skin antisepsis, other concentrations (e.g., 1, 4, 5 and 7.5%) available in different formulations (aqueous and alcoholic

solutions, scrub, gauzes, ointment and creams) are commonly used for various indications. The standard 10% for example, delivers 1% of biocidal, free molecular iodine (Capriotti and Capriotti, 2012). The American Dental Association has recently published interim guidelines for minimizing the risk of COVID-19 transmission which includes the use of a preoperative 0.2% povidone mouthwash (Estrich *et al.*, 2020). In human medicine, application of large quantities of povidone-iodine to open wounds is a common practice and there is a risk of significant toxicity for the patient. When systemically absorbed, iodine bound to serum albumin and is excreted by the kidneys; a clinical study of absorption and excretion of iodine after the administration of Betadine® by most routes, has shown that the blood levels correlate well with urine iodine levels (Ramaswamykanive. *et al.*, 2011).

Despite its apparent innocuousness, several cases of acute kidney injury (AKI) due to iodine toxicity have been documented. Toxicity was evident as a result of ingesting iodine tincture in a patient who attempted suicide (Mao *et al.*, 2011). AKI has also been reported in burn patients treated topically with povidone-iodine (Pietsch and Meakins, 1976). Recent study has shown apoptosis and necrosis related to povidone-iodine exposure induced time - and concentration dependent in cultured human epithelial cells and rat oral mucosal tissue (Sato *et al.*, 2014). Hence, administration of povidone-iodine through any route can subsequently result to its systemic absorption and consequently, it's accompanying toxicity. However, the amount of iodine absorbed varies with the concentration, the amount applied and route of administration (Glick *et al.*, 1985; Jose, 1986). Regardless of the ostensibly increasing usage of povidone-iodine, there is less information in scientific data about its safety and systemic evaluation in laboratory animals using the oral route; thus, its safety profile is needed. The oral LD₅₀ in

cockerels was found to be greater than 2,000 mg/kg body weight (Sani *et al.*, 2021), while studies on the acute oral toxicity of pure iodine in mice and rats revealed an LD₅₀ of 22,000 and 14,000 mg/kg, respectively (Alexander and Armen, 2013).

The clinical signs of iodine toxicity are nonspecific, anecdotal, sporadic and potentially fatal (Southern and Jwayyed, 2022). The minimum lethal dose of iodine in humans is unknown (Glick *et al.*, 1985). Although iodophors contain low free iodine levels, but the standard stock solution of Betadine® contains enough free iodine to cause systemic and lethal side effects (St. John *et al.*, 2015). The potential for allergic contact dermatitis associated with povidone-iodine has called for much debate and contention among dermatologists (Velázquez *et al.*, 2009). Therefore, the safety of povidone-iodine needs to be ascertained. In this study, acute oral toxicity profile of povidone-iodine was evaluated in mice.

MATERIALS AND METHODS

Source of chemical (Povidone-Iodine)

The chemical (Povidone-iodine 10% Solution) used was obtained from a commercial Nigerian pharmaceutical company (Jawa International Ltd., Isolo, Lagos, Nigeria).

Experimental animals

Ten male adult mice were obtained from the Faculty of Pharmaceutical Sciences, Ahmadu Bello University, Zaria; and were maintained in the same University throughout the study period at the animal house of the Department of Veterinary Pharmacology and Toxicology. Two plastic cages were obtained and disinfected; wood shavings were used as beddings and to each cage, a clean improvised drinker and feeder were attached. The mice were fed commercially prepared growers chick mash, and tap water provided *ad libitum*. The mice were kept at room temperature under fluorescent light, with 12 h light and 12 h dark cycle. One week was allowed for acclimatization, after which they

were randomly assigned groups (1 and 2, each consisting 5 mice).

Preparation of the limit dose

A limit dose (2000 mg/kg body weight of mice) of povidone-iodine (10% solution) was calculated to obtain a final volume (in ml) and used for this research.

Determination of acute oral toxicity of povidone-iodine

Based on a pilot study conducted, the LD₅₀ as an index of acute oral toxicity was determined. Hence, a limit dose (2000 mg/kg BW) was administered to each mouse and observed for 24 hours for instant death and possible signs of toxicity. The mice were further observed for 14 days for possible short-term effect and delayed toxicity (Bruce, 1985).

Evaluation of haematological parameters

Following light ether anaesthesia, the mice from both control and treated groups were sacrificed using jugular venesection and blood was collected into a labelled EDTA bottle for determination of haematological parameters. Following a standard technique involving the use of non-heparinized capillary tube, TG12MX® Micro-haematocrit centrifuge machine, and Hawksley® Micro-haematocrit reader, the packed cell volume was determined. Red and White blood cell counts were determined using Natt-Herrick solution (1:200 dilutions) and the improved Neubauer haemocytometer (Campbell and Ellis, 2007). The total White blood cell and differential White blood cell counts were determined by cytometer and Giemsa preparation on slides, respectively.

Determination of serum biochemistry

Following light ether anaesthesia, the mice from both control and treated groups were sacrificed using jugular venesection and blood was collected into a labelled plain bottle for determination of serum biochemical parameters. Serum alanine aminotransferase, aspartate aminotransferase, alkaline phosphatase activity, total protein levels, and urea were determined

using Randox assay kit (Randox Laboratories Ltd, Ardmore, Antrim, UK) according to manufacturer's instructions.

Histopathological examination

Kidneys and liver were harvested from sacrificed mice. The harvested organs were immediately fixed in 10 % formalin (Sigma-Aldrich, Inc., St. Louis, MO, USA) solution and then prepared for histological examination (Guntupalli *et al.*, 2006) with the aid of a light microscope, and the microscopic field images were captured.

Data analysis

All data generated were expressed as mean \pm standard error of mean (SEM) and subjected to independent t-test using Graphpad InStat (San Diego, CA). Values of $p \leq 0.05$ were considered statistically significant.

RESULTS

The limit dose (2,000 mg/kg) in mice

A single oral dose of povidone iodine® 2000 mg/kg body weight produced no signs of acute toxicity or immediate death in any of the mice tested (Table 1). All mice were observed for immediate death, 30 min later, and 24 h.

Effect of povidone-iodine administered at the limit dose (2,000 mg/kg of mice) on haematological parameters

On erythrocytic indices, no significant difference was observed between the treated and control groups. However, leucocytic indices showed a significant decrease ($p < 0.05$) in monocyte (monocytopenia) in the treated group when compared to the control, while no significant difference was observed in neutrophils and lymphocytes (Table 2).

Effect of povidone-iodine administered at the limit dose (2,000 mg/kg of mice) on serum biochemical parameters

Significant increase ($p < 0.05$) in the levels of Aspartate aminotransferase, Alanine aminotransferase, alkaline phosphatase and Blood urea nitrogen was observed in the treated group when compared to the control group.

However, no significant difference was observed in albumin, total protein and creatinine levels (Table 3).

Effect of povidone-iodine administered at the limit dose (2,000 mg/kg of mice) on histopathology of liver and kidney

Histopathological examination of the liver and kidney revealed no remarkable changes in the group treated with povidone iodine at Limit dose (2,000 mg/kg BW) when compared to the control. Intact central vein and hepatocytes were observed in the liver, while normal glomerulus and tubules were observed in the kidney for both treated and control groups (Figure 1).

DISCUSSION

Povidone-iodine is a synthetically produced topical antiseptic with a broad antimicrobial spectrum indicated for both treatment and prevention. Result showed the median lethal dose (LD₅₀) of povidone-iodine was found to be $>2,000$ mg/kg body weight. The benefits of povidone iodine include an excellent safety profile (United Nations Economic Commissions for Europe, 2005) and a broad spectrum of effect due to its multimodal action according to Eggers (2019), this may account for the safety observed in this study. Among other toxicity indices used in determining normal and pathological conditions in man and animals, toxic effects can be assessed using clinical as well as hematological findings and biochemical parameters (Sani *et al.*, 2010). After 14 days of observation, povidone-iodine administration at the limit dose of 2,000 mg/kg showed no significant change in the red blood cell indices and this agrees with previous works by Aletan (2014) in *Wistar* rats and Sani *et al.* (2021) in cockerels. This may be attributed to the release of iodine through indirect biotransformation from povidone iodine. Erythropoiesis is enhanced by the significant pathway of iodine metabolism in the synthesis of thyroxine and this in turn helps stabilize the erythrocytic indices (Ahmed and Mohammed, 2020).

Furthermore, the non-significant increase in the total white blood cell may be as a result of indirect enhanced myelopoietic effect by iodine via the action of thyroxine. Povidone iodine has been demonstrated to modulate the redox potential, inhibit the release of inflammatory mediators such as TNF- α and β -galactosidase, inhibit metalloproteinase production, and potentiate the healing signals from pro-inflammatory cytokines by activation of monocytes, T-lymphocytes, and macrophages (Bigliardi *et al.*, 2017). This may account for the monocytopenia observed in this study since the mechanism of action involves a great effect on monocytes (Ohtani *et al.*, 2007; Lepelletier *et al.*, 2020). Liver and kidney function parameters are important indicators for assessing damages or toxicity (Saleem *et al.*, 2017). On serum biochemistry, significant increases were recorded in AST, ALT, ALP and BUN in the treated group in comparison with the control group. Increased level of blood urea nitrogen is characteristic of kidney damage, and this was previously demonstrated when iodine containing

CONFLICT OF INTEREST

There is none to be declared.

REFERENCES

- Ahmed, S. S. and Mohammed, A. A. (2020). Effects of thyroid dysfunction on hematological parameters: Case controlled study. *Annals of Medicine and Surgery*, 57, 52-55.
- Aletan, U. I. (2014). Hematological effects following ingestion of *Allium cepa* (Onion), *Allium sativum* Garlic and treatment with iodine in Albino Wistar rats. *Pakistan Journal of Nutrition*, 13(8), 457.
- Alexander, I. and Armen N. (2013). Toxicology of iodine: A mini review. *Archives of Oncology*, 21, 65-71.
- Aliu, Y. O. (2007). *Veterinary Pharmacology*. Tamaza Publishing Company Ltd, Zaria, Kaduna State, Nigeria, pp. 432-435.
- Aliyu, H. B., Sa'idu, L., Jamilu, A., Andamin, A. D. and Akpavie S. O. (2016). Outbreaks of Virulent Infectious Bursal Disease in Flocks of Battery Cage Brooding System of Commercial Chickens. *Journal of Veterinary Medicine*, 81, 82-86.
- Bidra, A. S., Pelletier, J. S., Westover, J. B., Frank, S., Brown, S. M. and Tessema, B. (2020). Rapid in-vitro inactivation of severe acute respiratory syndrome coronavirus 2 (SARS-CoV-2) using povidone-iodine oral antiseptic rinse. *Journal of Prosthodontics*, 29, 529-533.
- Bigliardi, P.L., Alsagoff, S.A.L., El-Kafrawi, H.Y., Pyon, J.K., Wa, C.T.C. and Villa, M.A., (2017). Povidone iodine in wound healing: A review of current concepts

radiopaque materials were administered for imaging (Vaidya *et al.*, 2008; Fahling *et al.*, 2017). The results of the serum biochemistry agree with previous work by Kim *et al.* (2017). Chalasani *et al.* (2004) reported that regardless of the mechanism involved, reduced serum activities of aminotransferases have not been shown to correlate with the toxicologically significant outcome on the liver. Therefore, the increase in the activity of AST as seen in the treated group may not be attributed to toxic effect of PI, as indicated by the result of histopathology of the liver and kidney where no deleterious effect was observed.

CONCLUSION

Administration of povidone iodine at the limit dose of 2000 mg/kg showed no toxic effect in mice. Hence, this study showed the relative safety of PI at the administered dose.

ETHICAL APPROVAL

Approval for the ethical use and care of experimental animals was obtained from the Ahmadu Bello University Committee on Animal Use and Care.

- and practices. *International Journal of Surgery*, 44, 260-268.
- Bruce R. D. (1985). An up-and-down procedure for acute toxicity testing. *Fundamental of Applied Toxicology*. 5, 151-157.
- Campbell T. W. and Ellis C. K. (2007). Haematology of birds In: Campbell TW Ellis CK (eds) *Avian and Exotic Animal Haematology and Cytology* 3rd ed. Blackwell Publishing Professional Ames; pp. 3-50.
- Capriotti, K. and Capriotti, A. J. (2015). Chemotherapy-associated paronychia treated with a dilute povidone-iodine/dimethylsulfoxide preparation. *Clinical Cosmetic Investigative Dermatology*, 8, 489-491.
- Chalasanani, N., Aljadhey, H., Kesterson, J., Murray, M. D. and Hall, S.D. (2004). Patients with elevated liver enzymes are not at higher risk for statin hepatotoxicity. *Gastroenterol.* 126, 1287-1292.
- Eggers, M., Koburger-Janssen, T., Markus, E. and Juergen, Z. (2018). In vitro Bactericidal and Virucidal Efficacy of Povidone-Iodine Gargle/Mouthwash against Respiratory and Oral Tract Pathogens. *Infectious Disease Therapy*, 7, 249-259.
- Eggers, M. (2019). Infectious disease management and control with povidone iodine, *Infectious Disease Therapy*, 8, 581-593.
- Estrich, C. G., Mikkelsen, M., Morrissey, R., Geisinger, M. L., Ioannidou, E., Vujicic, M. and Araujo, M. W. (2020). Estimating COVID-19 prevalence and infection control practices among US dentists. *Journal of American Dental Association*, 151, 815-824.
- Fahling, M., Seeliger, E., Patzak, A. and Persson, P. B. (2017). Understanding and preventing contrast-induced acute kidney injury. *National Review of Nephrology*, 13, 169-180.
- Glick, L., Philip, M. D. B., Joseph, G., Robert, F. T. and Kevin, T. (1985). Iodine Toxicity in a Patient Treated by Continuous Povidone-Iodine Mediastinal Irrigation. *The Annals of Thoracic Surgery*, 39, 478-480.
- Guntupalli, M., Chandana, P., Pushpagadm, P. and Shirwaikar, A. (2006). Hepatoprotective Effects of Rubiadin, a Major Constituent of *Rubia cordifolia* Linn. *Journal of Ethnopharmacology*, 103, 484-490.
- Jean-Marie L., Olivier C., Alejandro F. C., Bernard L., Giuseppe M., Dominique T. and Julien, L. (2013). Antiseptics in the era of bacterial resistance: a focus on povidone iodine. *Clinical Practice*, 10, 579-592.
- Jose L. Z. (1986). Chemical and microbiologic characteristics and toxicity of povidone-iodine solutions. *American Journal of Surgery*, 151, 400-406.
- Kariwa, H., Fujii, N. and Takashima I. (2006). Inactivation of SARS Coronavirus by Means of Povidone-Iodine, *Physical Conditions and Chemical Reagents. Dermatology*, 212, 119-123.
- Kawana, R., Kitamura, T., Nakagomi, O., Matsumoto, I., Arita, M., Yoshihara, N., Yanagi, K., Yamada, A., Morita, O., Yoshida, Y., Furuya, Y. and Chiba, S. (1997). Inactivation of Human Viruses by Povidone-Iodine in Comparison with Other Antiseptics. *Dermatology*, 195, 23-30.
- Kim, C. S., Kim, S. S., Bae, E. H., Ma, S. K. and Kim, S. W. (2017). Acute kidney injury due to povidone-iodine ingestion: a case report. *Medicine*, 96, 79-88.
- Lepelletier, D., Maillard, J. Y., Pozzetto, B. and Simon, A. (2020). Povidone iodine: properties, mechanisms of action, and role in infection control and *Staphylococcus aureus* decolonization. *Antimicrobial Agents of Chemotherapy*, 64, 00682-20.
- Lipsky, B. A. and Hoey, C. (2009). Topical antimicrobial therapy for treating chronic wounds. *Clinical Infectious Disease*, 49, 1541-1549.
- Mao, Y. C., Tsai, W. J., Wu, M. L., Ger, J., Deng, J. F. and Yang, C. C. (2011). Acute hemolysis following iodine tincture ingestion. *Human Experimental Toxicology*, 30, 1716-1719.

- Ohtani, T., Mizuashi, M., Ito, Y. and Aiba S., (2007). Cadexomer as well as cadexomer iodine induces the production of proinflammatory cytokines and vascular endothelial growth factor by human macrophages. *Experimental Dermatology*, 16, 318-323.
- Pietsch, J. and Meakins, J. L. (1976). Complications of povidone-iodine absorption in topically treated burn patients. *Lancet*, 1, 280-282.
- Ramaswamykanive, H., Nanavati, Z., Mackie, J., Linderman, R. and Lavee, O. (2011). Cardiovascular Collapse following Povidone-Iodine Wash. *Anesthetic Intensive Care*, 39, 1-10.
- Ripa, S., Nancy, B., Robert, F., Reder, C., Robert, I. R. (2002). Clinical Applications of Povidone-Iodine as a Topical Antimicrobial. *Handbook of Topical Antimicrobials*, 1st Edition, Imprint CRC Press, pp. 22.
- Saleem, U. S. Amin, B., Ahmad, H., Azeem, F. and Mary, S. (2017). Acute oral toxicity evaluation of aqueous ethanolic extract of *Saccharum munja* Roxb. Roots in albino mice as per OECD 425 TG. *Toxicology Report*, 1, 580-585.
- Sani, D., Sanni, S., Sandabe, U. K., Ngulde, S. I. (2010). Toxicological studies on *Anisopus mannii* crude aqueous stem extract: biochemical and histopathological effects in albino rats. *International Journal of Pharmaceutical Sciences*, 2, 51-59.
- Sani, D., Abdu, P. A., Mamman, M., Jolayemi, K. O., Yusuf, P. O., Andamin, A. D. (2021). Evaluation of acute oral toxicity of povidone-iodine in cockerels using the up-and-down procedure. *Poultry Science*, 100, 631-634.
- Sato, S., Miyake, M., Hazama, A. (2014). Povidone-iodine-induced cell death in cultured human epithelial HeLa cells and rat oral mucosal tissue. *Drug and Chemical Toxicology*, 37, 268-275.
- St. John, Alexander E., Wang Xu, Lim Esther B., Chien, Diana, Stern Susan, A. and White, N. J. (2015). Effects of rapid wound sealing on survival and blood loss in a swine model of lethal junctional arterial hemorrhage. *Journal of Trauma and Acute Care Surgery*, 79, 256-262.
- Southern, A. P., and Jwayyed, S. (2022). Iodine toxicity. In: *StatPearls* [Internet]. Treasure Island (FL): StatPearls Publishing; 2023 Jan-. PMID: 32809605.
- United Nations Economic Commissions for Europe (2005). *Globally Harmonized System of Classification and Labelling of Chemicals (GHS). The Purple Book*. New York, Geneva: United Nations Economic Commission for Europe, pp. 60.
- Vaidya, V. S., Ferguson, M. A., Bonventre, J. V. (2008). Biomarkers of acute kidney injury. *Annual Review of Pharmacology and Toxicology*, 48, 463-493.
- Velázquez, D., Zamberk, P., Suárez, R. and Lázaro, P. (2009). Allergic contact dermatitis to povidoneiodine. *Contact Dermatology*, 60, 348-349.
- Wood, A. and Payne, D., (1998). The action of three antiseptics/disinfectants against enveloped and non-enveloped viruses. *Journal of Hospital Infection*, 38, 283-295.

Figure Legend

Fig. 1. Photomicrograph of kidney and liver and kidney of mice. CV; central vein, G; glomerulus, T; tubules. H & E stain × 200.

Table 1: Effect of oral administration of povidone iodine at limit dose of 2000 mg/kg in mice

Experimental mice	Mice label	Dose (mg/kg)	Short-term effect (24 hrs)	Delayed effect (14 days)
I	B	2000	No death	No death
II	H	2000	No death	No death
III	T	2000	No death	No death
IV	FL	2000	No death	No death
V	HL	2000	No death	No death

Key: H (Head), B (Back), T (Tail), FL (Forelimb), HL (Hindlimb).

Table 2: Haematological parameters of male adult mice orally administered a limit dose (2,000 mg/kg) of povidone-iodine

Parameters	Control	Treated (2000 mg/kg)
Total Red Blood Cells (x10 ⁹ /L)	5.33 ± 0.58	4.47 ± 0.85
Packed cell volume (%)	43.67 ± 0.58	39.67 ± 7.51
Haemoglobin (g/dL)	14.47 ± 0.15	12.97 ± 2.35
Total White Blood Cells (x10 ⁹ /L)	9.70 ± 0.90	11.50 ± 2.50
Neutrophils (%)	35.67 ± 7.51	33.67 ± 5.51
Lymphocyte (%)	63.00 ± 8.00	62.67 ± 7.51
Monocyte (%)	3.00 ± 3.00	0.67 ± 0.58*

Data are expressed as mean ± SEM, n=5. Means in the same row with different superscript for each parameter are statistically significant (*p < 0.05).

Table 3: Biochemical parameters of male adult mice orally administered a limit dose (2,000 mg/kg) of povidone-iodine

Parameters	Control	Treated (2000 mg/kg)
Aspartate aminotransferase (U/L)	125.67 ± 6.11	273.00 ± 2.00*
Alanine aminotransferase (U/L)	26.00 ± 7.00	87.67 ± 7.51*
Alkaline phosphatase (U/L)	63.67 ± 5.50	78.67 ± 2.52*
Albumin(g/L)	2.93 ± 0.12	2.37 ± 0.25
Creatinine (mg/dL)	0.87 ± 0.06	0.90 ± 0.10
Blood urea nitrogen (mg/L)	55.33 ± 3.51	83.00 ± 5.00*
Total protein (g/L)	7.80 ± 0.20	9.77 ± 0.25

Data are expressed as mean ± SEM, n=5. Means in the same row with different superscript for each parameter are statistically significant (*p < 0.05).

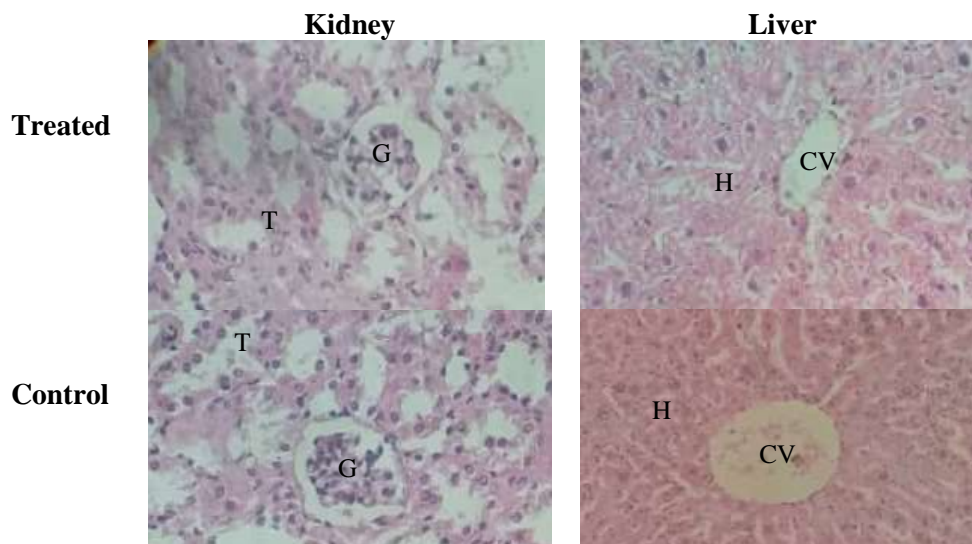


Figure 1: Photomicrograph of kidney and liver and kidney of mice (H & E stain $\times 200$). CV; central vein, G; glomerulus, T; tubules, H; hepatocytes.