



## Research Article

# Histochemical Demonstration of Fungi in Breast Diseases at University of Maiduguri Teaching Hospital-North Eastern Nigeria

Chiwar HM<sup>1,2</sup>, Suleiman N<sup>1</sup>, Zarami AB<sup>3,4</sup>, Ahmed M<sup>1,4</sup>, Bulama HU<sup>4</sup> and Ahmed UM<sup>4</sup>

<sup>1</sup>Department of Medical Laboratory Science, College of Medical Sciences, University of Maiduguri, Nigeria

<sup>2</sup>African Centre of Excellence for Neglected Tropical Diseases and Forensic Biotechnology, Ahmadu Bello University, Zaria, Nigeria

<sup>3</sup>Department of Human Pathology, College of Medical Sciences, University of Maiduguri, Nigeria

<sup>4</sup>Department of Histopathology, University of Maiduguri Teaching Hospital, Borno State, Nigeria

\*Corresponding author: [alaskiry@gmail.com](mailto:alaskiry@gmail.com), [doi.org/10.55639/607.858483](https://doi.org/10.55639/607.858483)

## ARTICLE INFO:

### Keywords:

Breast cancer,  
Fungal infections,  
Histochemical staining,  
FFPE tissue,  
Cross-sectional study

## ABSTRACT

Breast disease is a global public health concern, and recent research suggests that fungal infections may be linked to its development and progression. This study aims to investigate the presence of fungi in formalin-fixed paraffin-embedded (FFPE) breast tissue samples diagnosed with various breast diseases, including breast cancer, using histological staining techniques. The study design was a retrospective cross-sectional study that used convenience sampling to retrieve 49 breast tissue blocks diagnosed with various breast diseases from the Histopathology archive of the University of Maiduguri Teaching Hospital, Nigeria. The samples were re-embedded with paraffin wax, sectioned, and stained using Haematoxylin and Eosin and Grocott Methanamine Silver Stain. The data collected was analyzed descriptively and using chi-square tests. Fibroadenoma was the most common diagnosis in the study (69.3%), followed by Chronic Granulomatous Mastitis (18.4%) and breast cancer (12.2%). The highest frequency of Fibroadenoma diagnosis was in the age range of 30-39, whereas the highest frequency of breast cancer diagnosis was in the age range of 20-29. The study found that fungal infections were present in breast tissue samples, and the highest percentage of positive Gomori Methenamine Silver (GMS) stain test results were found in breast disease cases with breast cancer with a significant p value of 0.0175. This study provides evidence of a potential association between fungal infections and breast diseases in North Eastern Nigeria. Further research is needed to fully understand the mechanisms underlying this association and its implications for breast cancer prevention and treatment.

Corresponding author: Chiwar HM Email: [alaskiry@gmail.com](mailto:alaskiry@gmail.com)

Department of Medical Laboratory Science, College of Medical Sciences, University of Maiduguri, Nigeria

## INTRODUCTION

Breast diseases, including breast cancer, continue to be a significant public health concern worldwide (Sung *et al.*, 2021). According to the World Health Organization (WHO), breast cancer is the most common cancer among women, with an estimated 2.3 million new cases diagnosed in 2020 (WHO, 2021). While the etiology of breast cancer remains poorly understood, a growing body of research suggests that fungal infections may be involved in the development and progression of this disease.

Fungal infections have been implicated in a diverse range of human diseases, including cancer (Kaneko *et al.*, 2016). They possess a remarkable ability to evade the immune system and can produce toxins that damage DNA and cellular components (Gonçalves *et al.*, 2017). Specific fungal species, like *Candida albicans*, *Cryptococcus neoformans*, and *Aspergillus fumigatus*, have been identified in breast cancer tissue (Banerjee *et al.*, 2019; Gharib *et al.*, 2019; Kaur *et al.*, 2017), leading to suggestions that fungal infections may be linked to the initiation or progression of breast cancer. Moreover, fungi might influence the breast tissue microbiome, triggering an inflammatory response that fosters cancer development (Banerjee *et al.*, 2019). Despite mounting evidence, further research is necessary to fully comprehend the role of fungi in breast diseases.

With the potential role of fungi in breast diseases, there's a growing need for innovative diagnostic and therapeutic approaches. One promising method involves using histological techniques, like PAS and GMS staining, to visualize fungal infections in breast tissue samples (Singh *et al.*, 2018). While these techniques have been successful in other tissues, more research is required to confirm their utility in breast tissue.

Histological staining techniques, such as periodic acid-Schiff (PAS) staining and Gomori methenamine silver (GMS) staining, are commonly used to detect fungi in tissue samples (Kwon-Chung and Bennett, 1992). Formalin fixed paraffin embedded (FFPE) tissue samples are routinely collected and stored in pathology departments for diagnostic purposes, making them a valuable resource for retrospective studies. FFPE breast tissue samples have been used in previous studies to investigate the presence of viral infections in breast cancer tissue (Glenn and Hengartner, 2011), but to our knowledge, no study has examined the presence of fungal infections in FFPE breast tissue samples from patients with various breast diseases in North Eastern Nigeria.

Therefore, the objective of this study is to investigate the presence of fungi in FFPE breast tissue samples diagnosed with various breast diseases, including breast cancer, using histological staining techniques. Specifically, the study aims to use GMS staining to identify fungal infections in FFPE breast tissue samples from patients who underwent breast surgery at University of Maiduguri Teaching Hospital. The distribution of fungal infections will also be examined in relation to age and gender. By doing so, new insights may be gained into the potential role of fungal infections in the development and progression of breast diseases in this region. Additionally, this study may reveal novel diagnostic and therapeutic targets for breast diseases associated with fungal infections.

## MATERIALS AND METHOD

### Study Design

Study type: This study is a cross-sectional retrospective study.

### Sample size and Study Area

The study sample size is 49 formalin fixed paraffin-embedded breast tissue blocks diagnosed with various breast diseases

retrieved from the Histopathology archive of University of Maiduguri Teaching Hospital (UMTH) between January 2021 and December 2021.

**Sampling method:** The samples were retrieved from the Histopathology archive of the University of Maiduguri Teaching Hospital (UMTH) using convenience sampling.

**Sample Preparation:** The 10% buffered formalin-fixed and paraffin-embedded tissues were retrieved from the Histopathology Department UMTH archive and re-embedded with molten paraffin wax. To expose the complete surface of the tissues, the blocks were trimmed at 0 micrometers using a Leica microtome and placed on an ice tray until sectioning. Subsequently, sections of 3 micrometers were cut and placed on a float plate flooded with 20% alcohol, floated onto a water bath at 40 degrees Celsius to stretch, and then picked up with a clean albuminised glass slide. The slides were then placed on a hot plate at 60 degrees Celsius for 20 minutes to dry and ensure adherence of the sections onto the slides.

**Staining Methods:** The following staining methods were used: i. Haematoxylin and Eosin (H&E) for demonstration of general tissue structure ii. Grocott Methanamine Silver Stain (GMS) for demonstrating the presence of fungal organisms.

**Haematoxylin and Eosin Staining Technique:** The H&E staining technique was used to demonstrate of general tissue structure. The sections were deparaffinized, hydrated, and then stained with haematoxylin for 10 minutes. After differentiating in 1% acid alcohol and rinsing in tap water all briefly, the sections were stained with eosin for 1 minute.

The sections were then dehydrated, cleared in xylene, and mounted with DPX mounting medium.

**Grocott Methanamine Silver Stain:** The GMS staining technique was used to demonstrate the presence of fungal organisms. The sections were deparaffinized, hydrated, and then stained with Grocott's methenamine silver solution for 1 hour. The sections were then rinsed in distilled water, counterstained with light green for 5 minutes, dehydrated, cleared in xylene, and mounted with DPX mounting medium.

**Data analysis:** The data collected from the study was analyzed descriptively. The frequency and percentage of fungal infections in breast tissue samples were determined, and the results were presented in tables and micrographs. Chi-square test was used to determine the association between the presence of fungal infections and types of breast diseases as well as age and gender.

**Ethical considerations:** The study utilized archived formalin-fixed paraffin-embedded (FFPE) tissue samples, and did not involve human subjects or animals; therefore ethical clearance was not required.

## **RESULTS**

**Table 1, Age Distribution:** Overall, there were 49 breast disease cases in the study. The largest age group was 30-39, with 19 breast disease cases, representing 38.8% of the total. The next largest group was 20-29, with 11 breast disease cases (22.4%), followed by 40-49 with 10 breast disease cases (20.4%). The age group with the fewest breast disease cases was 50-59, with only one breast disease case, representing just 2.0% of the total.

**Table 1:** Age Distribution:

| Age range | Frequency | Percent |
|-----------|-----------|---------|
| 10-19     | 8         | 16.3    |
| 20-29     | 11        | 22.4    |
| 30-39     | 19        | 38.8    |
| 40-49     | 10        | 20.4    |
| 50-59     | 1         | 2.0     |
| Total     | 49        | 100.0   |

The majority of breast disease cases in the study were diagnosed with fibroadenoma, with 34 breast disease cases (69.3%) having this condition. Chronic Granulomatous Mastitis was the second most common diagnosis, with

9 breast disease cases (18.4%) having this condition. Breast cancer was the least common diagnosis, with 6 breast disease cases (12.2%) having this condition (Table 2).

**Table 2:** Distribution of Breast diseases:

| Diagnosis                            | Frequency | Percent |
|--------------------------------------|-----------|---------|
| Fibroadenoma                         | 34        | 69.3    |
| Chronic<br>Granulomatous<br>Mastitis | 9         | 18.4    |
| Breast Cancer                        | 6         | 12.2    |
| Total                                | 49        | 100     |

Distribution of Histopathological Diagnoses of Breast Conditions by Age Range: The table shows the number of breast disease cases with each histopathological diagnosis (Fibroadenoma, Chronic Granulomatous Mastitis, and Breast Cancer) for each age range, as well as the total number of breast disease cases in each age range (Table 3).

Looking at the table, we can see that the most common histopathological diagnosis across all age ranges was Fibroadenoma. The highest frequency of Fibroadenoma diagnosis was in

the age range of 30-39, with 12 breast disease cases. In contrast, the least common diagnosis across all age ranges was Breast Cancer. The highest frequency of Breast Cancer diagnosis was in the age range of 20-29, with 3 breast disease cases.

Another notable finding in the table is that Chronic Granulomatous Mastitis was more common in younger age groups, with 2 breast disease cases in the 20-29 age range and 5 breast disease cases in the 30-39 age range, but was rare in the older age groups.

**Table 3:** Distribution of Histopathological Diagnoses of Breast Conditions by Age Range

| Age-range    | Histopathological Diagnosis |                                |               | Total     |
|--------------|-----------------------------|--------------------------------|---------------|-----------|
|              | Fibroadenoma                | Chronic Granulomatous Mastitis | Breast Cancer |           |
| 10-19        | 7                           | 1                              | 0             | 8         |
| 20-29        | 6                           | 2                              | 3             | 11        |
| 30-39        | 12                          | 5                              | 2             | 19        |
| 40-49        | 8                           | 1                              | 1             | 10        |
| 50-59        | 1                           | 0                              | 0             | 1         |
| <b>Total</b> | <b>34</b>                   | <b>9</b>                       | <b>6</b>      | <b>49</b> |

Distribution of GMS Stain Test Results by Histopathological Diagnosis of Breast Diseases: This is a cross-tabulation table that shows the results of the Gomori Methenamine Silver (GMS) stain test for histopathological diagnoses of breast conditions. The table displays the number and percentage of breast disease cases with each diagnosis (Fibroadenoma, Chronic Granulation, and Breast Cancer) who tested positive or negative for the GMS stain, as well as the total number

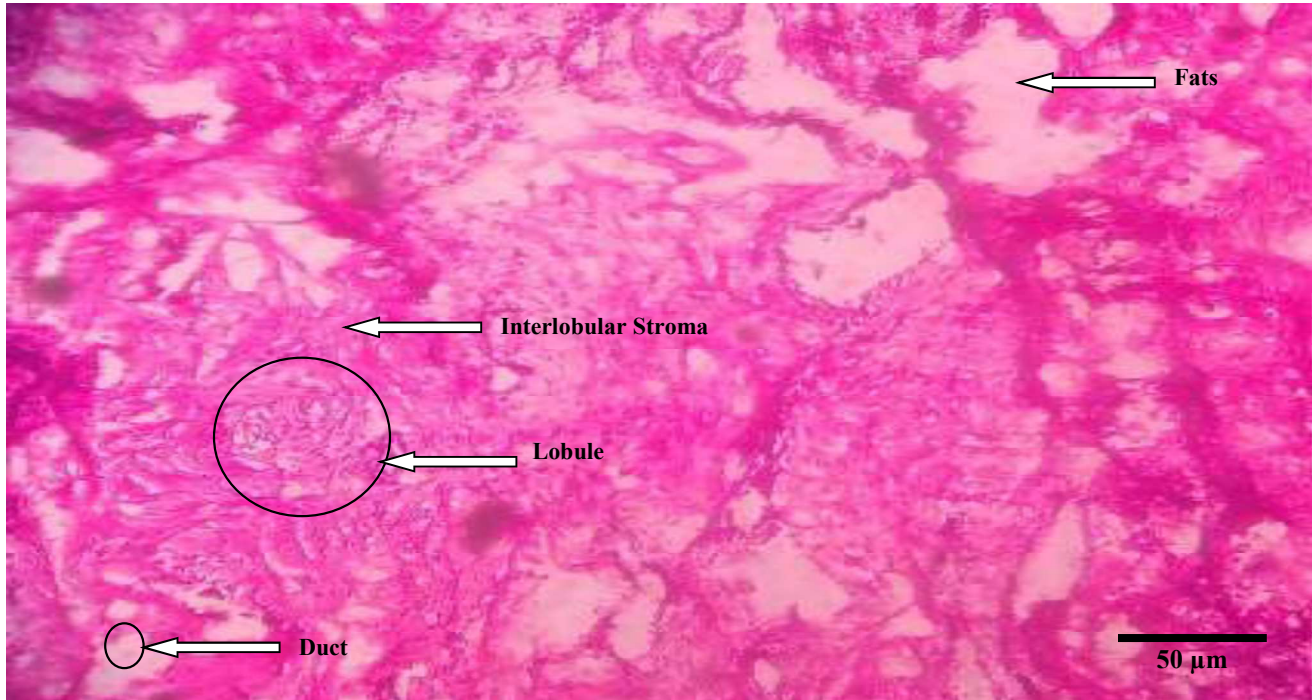
of breast disease cases for each diagnosis (Table 4).

The table reveals that the highest percentage of positive GMS stain test results was found among breast disease cases with Breast Cancer (83.3%), followed by breast disease cases with Fibroadenoma (70.6%). In contrast, only 44.4% of breast disease cases with Chronic Granulomatous Mastitis tested positive for the GMS stain.

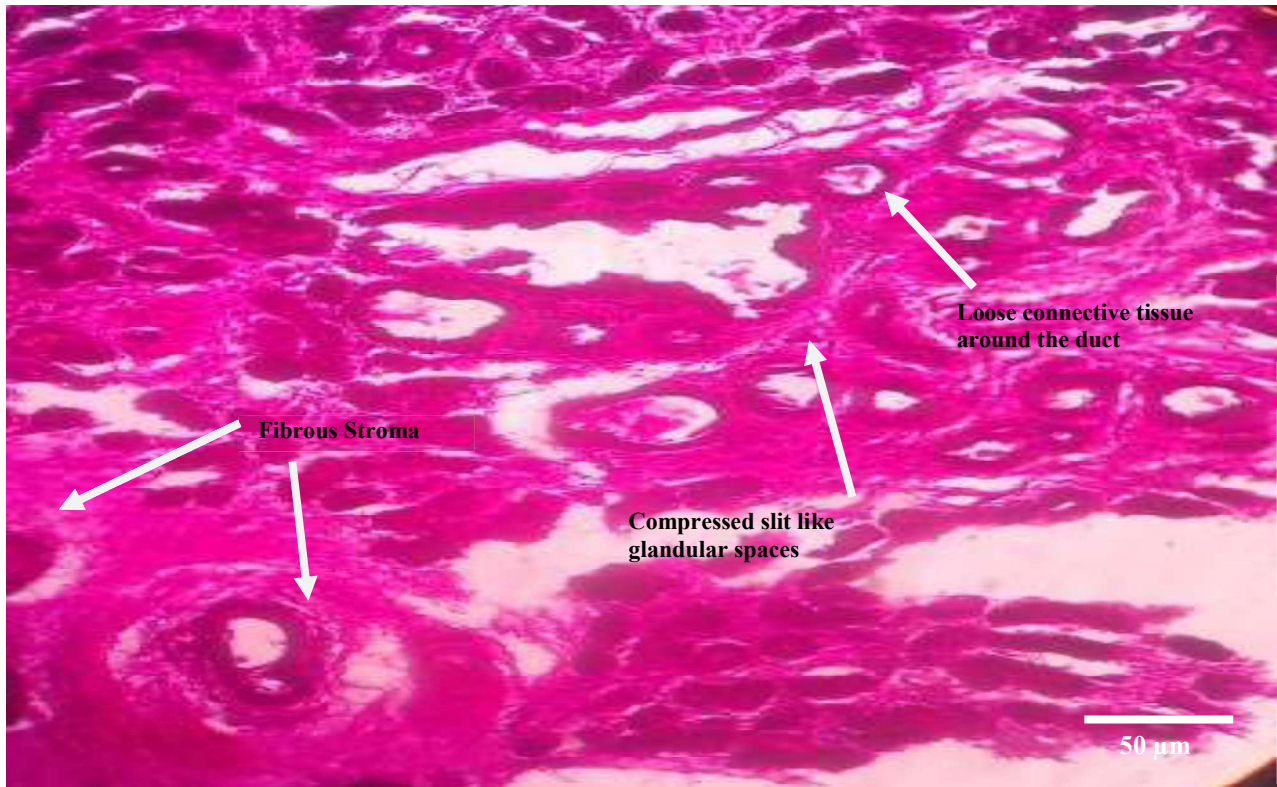
**Table 4:** Distribution of GMS Stain Test Results by Histopathological Diagnosis of Breast Diseases:

| Histopathological Diagnosis    | GMS                 |                     |                         |                     | Total     |
|--------------------------------|---------------------|---------------------|-------------------------|---------------------|-----------|
|                                | Reactive (Positive) | Percentage positive | Non-Reactive (Negative) | Percentage Negative |           |
| Fibroadenoma                   | 24                  | 70.6%               | 10                      | 29.4%               | 34        |
| Chronic Granulomatous Mastitis | 4                   | 44.4%               | 5                       | 55.6%               | 9         |
| Breast Cancer                  | 5                   | 83.3%               | 1                       | 16.7%               | 6         |
| <b>Total</b>                   | <b>33</b>           |                     | <b>16</b>               |                     | <b>49</b> |

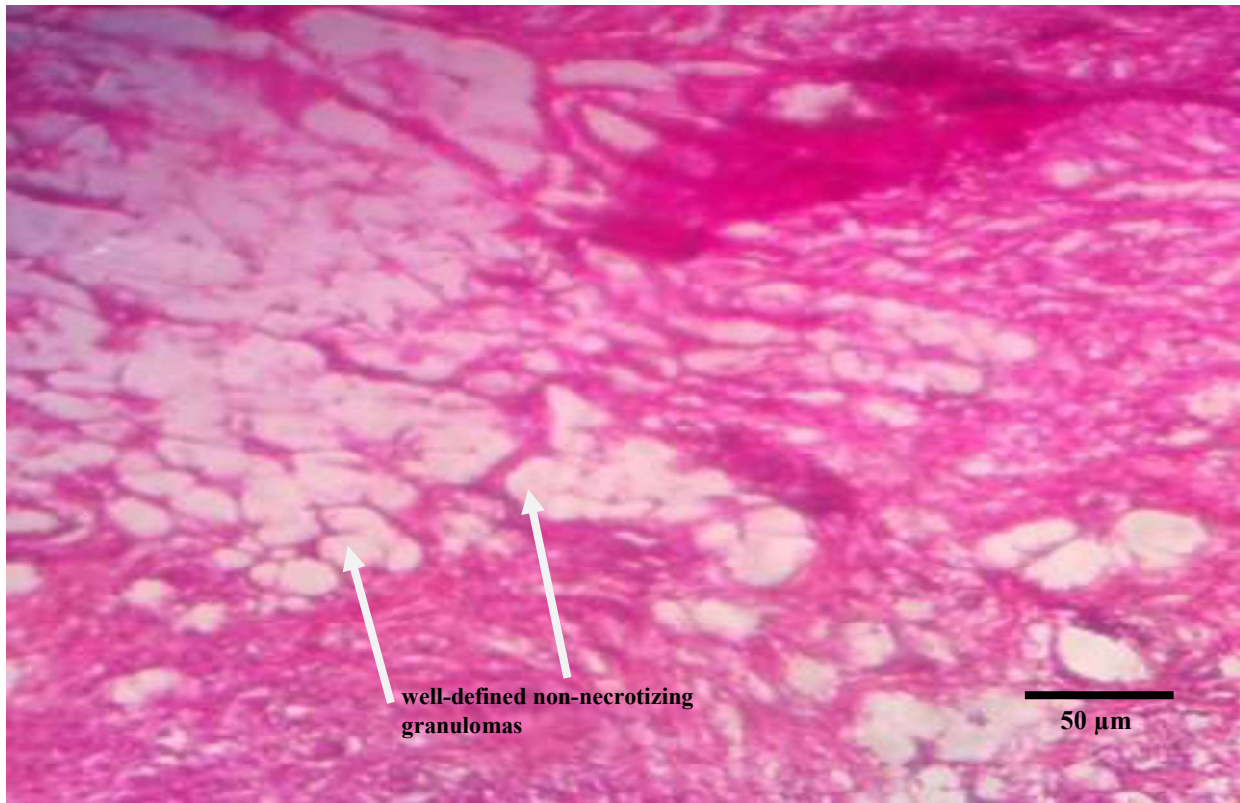(p-value is 0.0175)



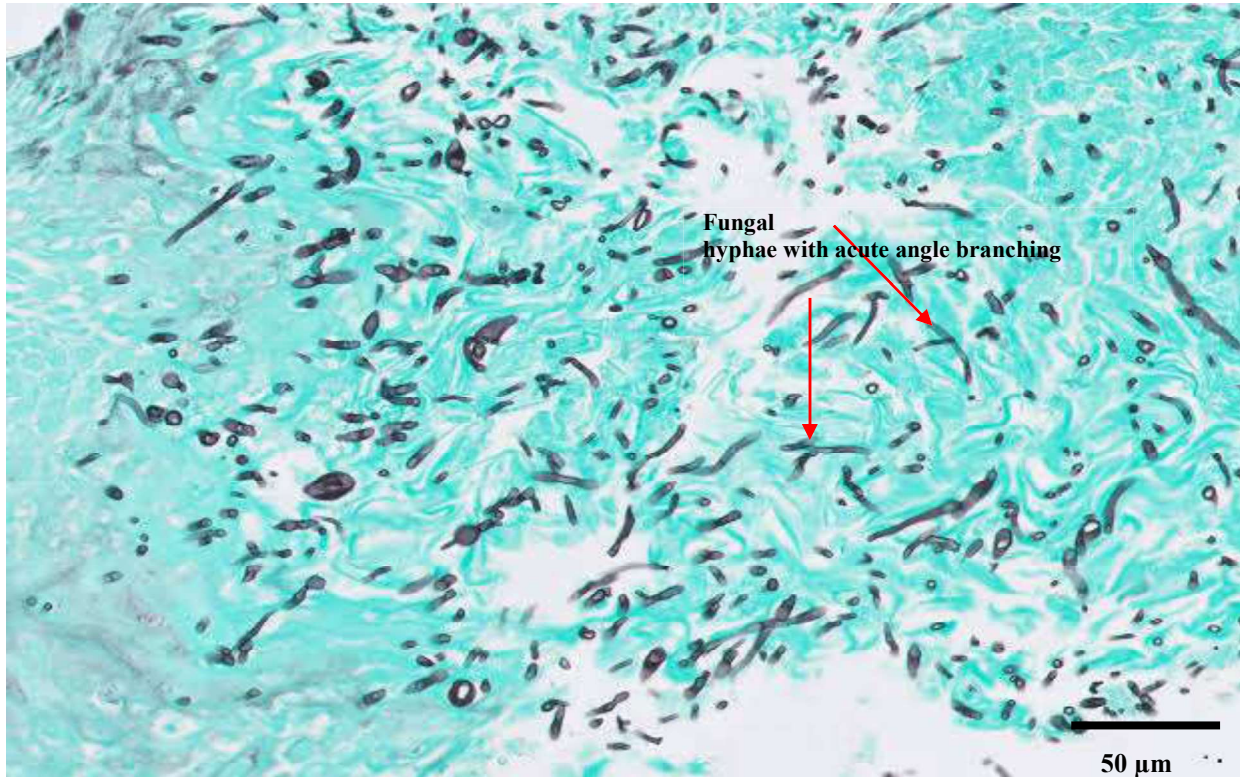
**Figure 1:** Haematoxylin and Eosin stain, demonstrating normal breast tissue (bar = 50 microns)



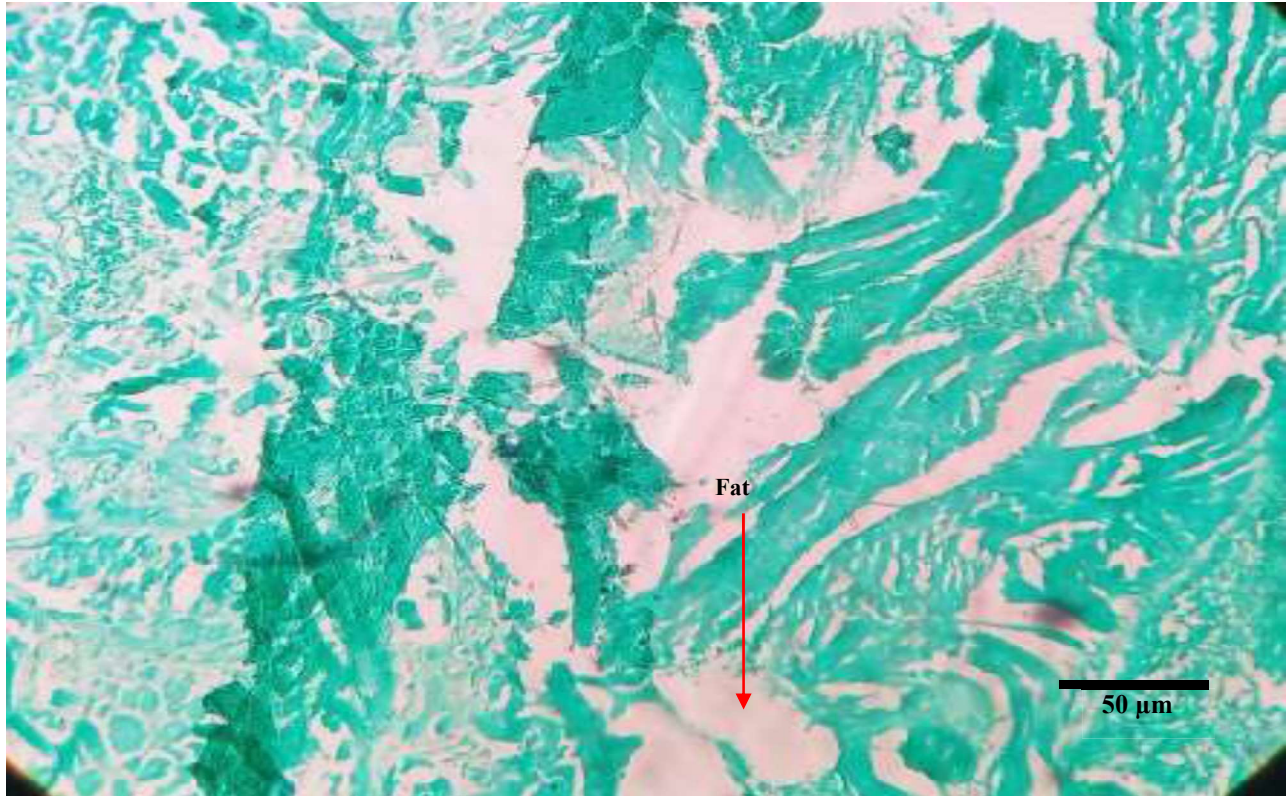
**Figure 2:** Hematoxylin and Eosin Stain, showing breast fibroadenoma (bar = 50 microns).



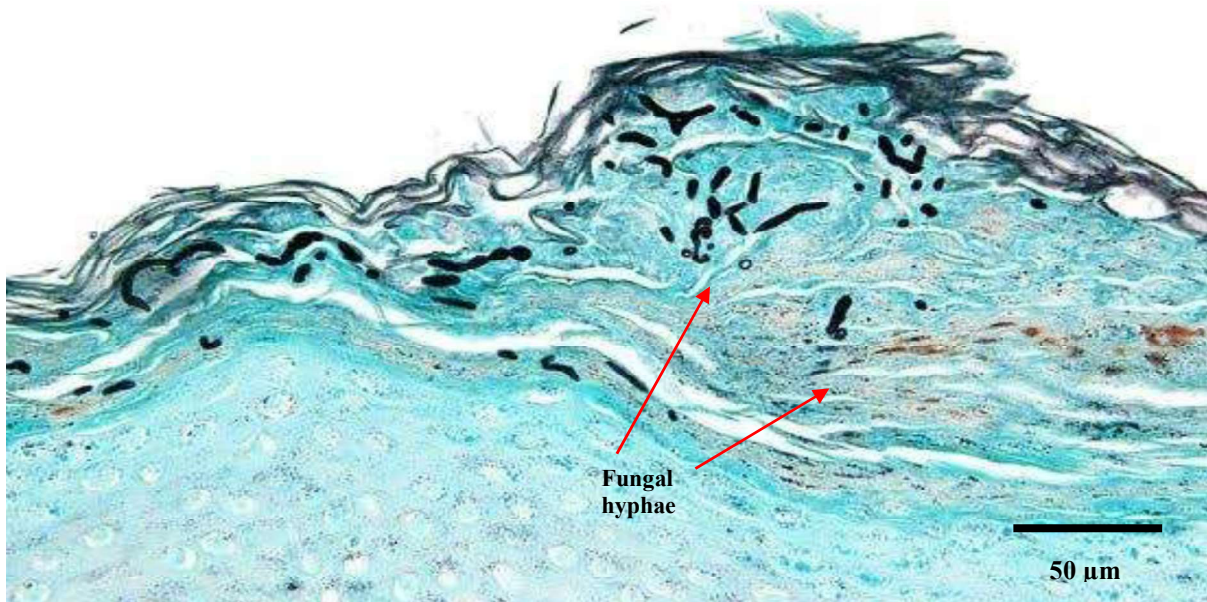
**Figure 3:** Hematoxylin and Eosin Stain, showing chronic granulomatous mastitis (bar = 50 microns).



**Figure 4:** Gomori's methenamine silver (GMS) stain, demonstrating fungal hyphae with acute angle branching (positive control slide, bar = 50 microns)

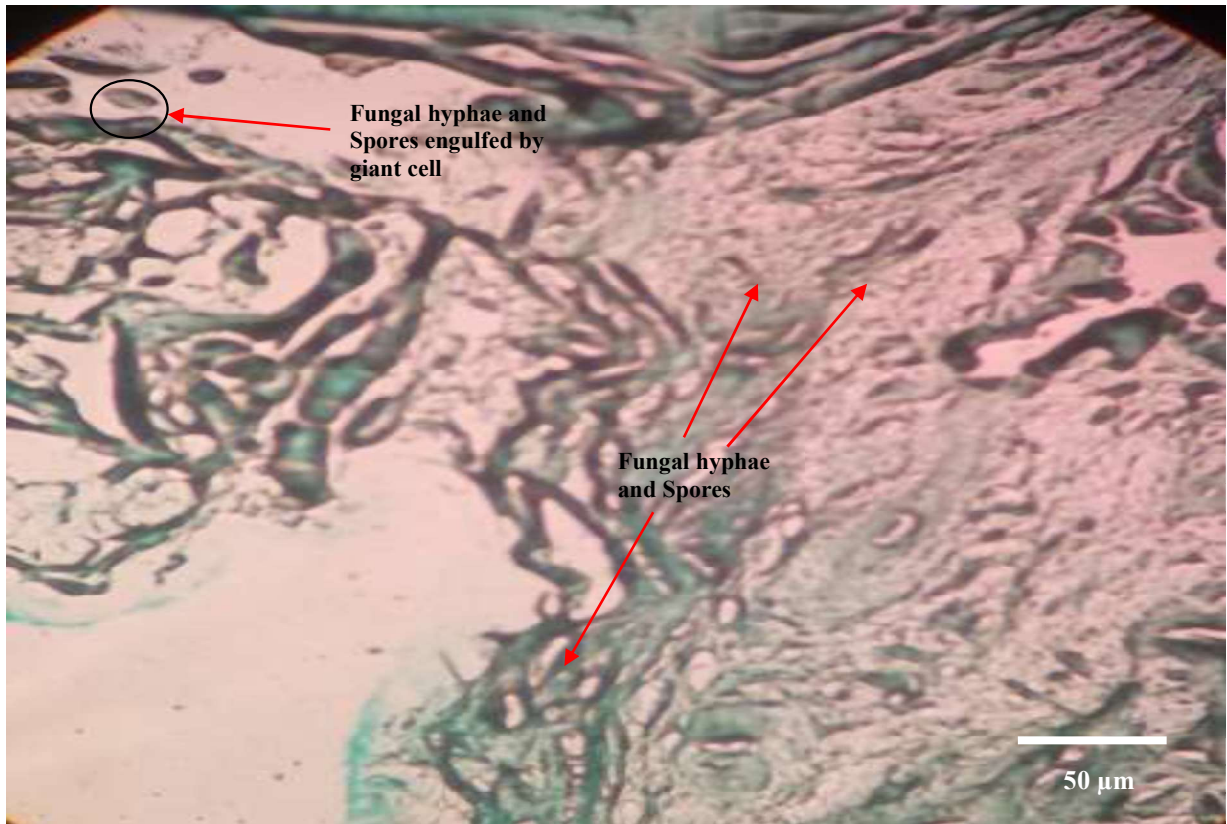


**Figure 5:** Gomori's methenamine silver (GMS) stain, demonstrating Normal breast tissue, no fungal hyphae or spores (Negative control, bar = 50 microns).

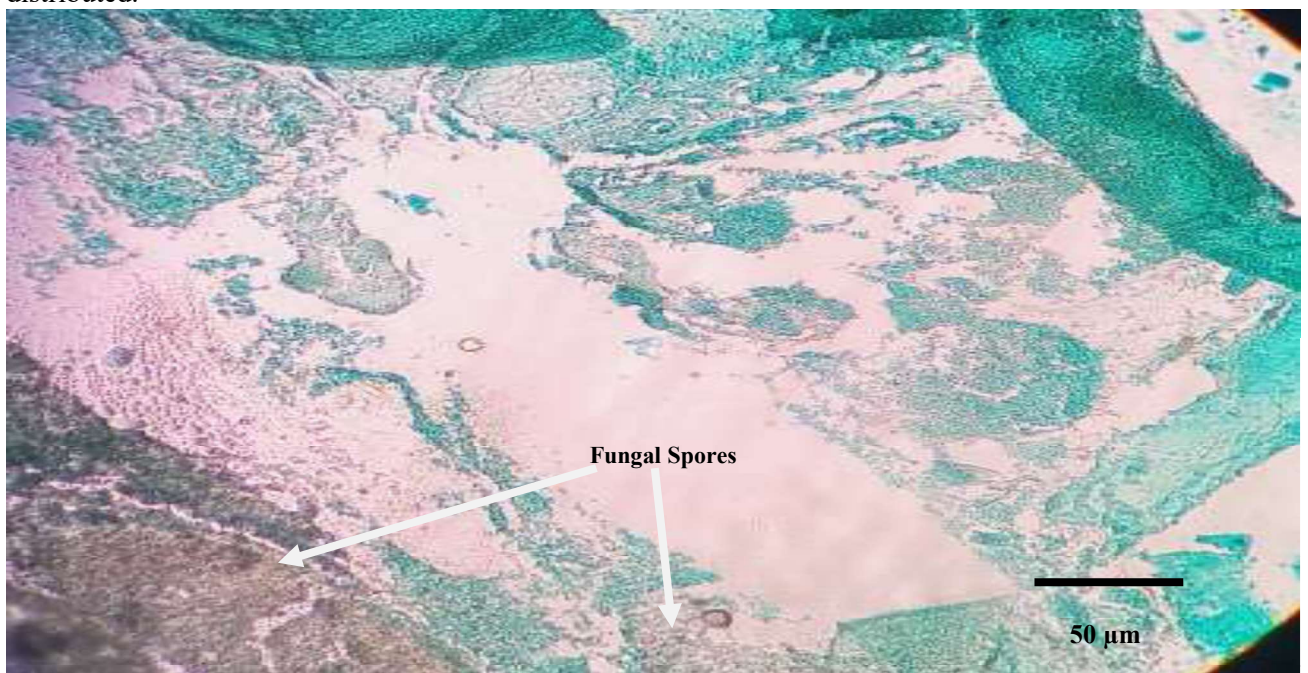


**Figure 6:** Fungal hyphae highlighted by the Grocott methenamine silver special stain; hyphae with nonparallel walls, non-dichotomous branching, and terminal bulbous dilations in breast fibroadenoma.





**Figure 7:** Fungal hyphae and spores highlighted by the Grocott methenamine silver special stain in breast cancer. Fungal hyphae with parallel walls and dichotomous branching, spores finely distributed.



**Figure 8:** chronic granulomatous mastitis stained with Grocott methenamine silver reveals are clear, brown-black, round fungal spores (arrow) with different sizes against the bright green and clean background.

## DISCUSSION

Worldwide, breast diseases are a significant public health concern, particularly breast cancer. This study's objective was to explore the presence of fungi in FFPE breast tissue samples diagnosed with different breast diseases, including breast cancer; using histological staining techniques and the research specifically targeted the population in North Eastern Nigeria.

The age distribution of breast disease cases in the study is consistent with previous research in Nigeria and other African countries. While breast cancer typically affects Nigerian women at an earlier age compared to Western countries, with a peak age group of 40-49 years, the largest age group with breast disease cases in this study was 30-39 years, representing 38.8% of the total cases. Similar findings were reported in a study conducted in Ghana, which also observed a higher proportion of breast cancer cases in the 30-39 age group. The reasons for this age-related variation in breast diseases remain unclear, but hormonal differences between premenopausal and postmenopausal women are suggested to play a role.

In Nigeria and other African countries, younger women may have a higher incidence of breast diseases due to genetic susceptibility, environmental influences, lifestyle choices, and limited access to early detection and treatment. A Nigerian study specifically found a higher prevalence of the BRCA1 gene mutation, which is associated with increased breast cancer risk, in Nigerian women with early-onset breast cancer (Echendu *et al.*, 2021).

Early detection and treatment are crucial for improving breast cancer outcomes and reducing mortality. However, limited access to screening and diagnostic services remains a challenge in low- and middle-income countries, including Nigeria (Gwarzo *et al.*,

2019). This highlights the need for increased investments in healthcare infrastructure and resources to improve access to early detection and treatment of breast diseases in Nigeria.

Regarding histopathological diagnoses, fibroadenoma was the most prevalent breast disease, comprising 69.3% of the cases. Chronic granulomatous mastitis was the second most common diagnosis (18.4%), followed by breast cancer (12.2%). The GMS stain test revealed the highest percentage of positive results in breast cancer cases (83.3%), followed by fibroadenoma cases (70.6%), and the lowest positive rate was observed in chronic granulomatous mastitis cases (44.4%). The study indicates a potential link between fungal infections and breast cancer in the Nigerian population. Similar findings have been reported in studies from other African countries, where fungal DNA was detected in breast cancer samples at higher rates compared to benign breast tissue (Banerjee *et al.*, 2015; Ezzat *et al.*, 2016; Salehi *et al.*, 2015).

The calculated p-value of 0.0175 indicates a statistically significant association between histopathological diagnosis of breast disease and GMS stain test results. This suggests that the GMS stain test can be a valuable diagnostic tool in identifying breast cancer cases in Nigeria. However, chronic granulomatous mastitis cases showed a lower positive rate, suggesting that this condition may not be associated with fungal infections.

## CONCLUSION

The study suggests the presence of fungal infections in breast tissue samples from patients with various breast diseases, including breast cancer. Identifying fungal infections through histological staining techniques could offer new insights and lead to innovative diagnostic and treatment approaches. Further research is needed to explore the role of fungal infections and other microorganisms in breast

diseases and develop effective prevention and management strategies

### LIMITATION

During the course of this study, we encountered challenges related to sample availability. Despite the initial goal of obtaining a larger sample size, only 49 formalin-fixed paraffin-embedded (FFPE) breast tissue samples were accessible from the histopathology archive of the University of Maiduguri Teaching Hospital between January and December 2021. Another critical aspect that affected sample availability was that FFPE breast tissues were required to have detailed clinical and pathological documentation to be included in the study.

Therefore, the results may not be generalizable to other regions or populations. In addition, the study did not examine the potential role of other microorganisms, such as bacteria and viruses, in the development and progression of breast diseases.

Further studies with larger sample sizes and a multicenter approach are needed to confirm the findings of this study and investigate the potential role of other microorganisms in breast diseases.

### CONFLICT OF INTEREST

The authors declare no conflict of interest. All authors have disclosed any financial and personal relationships with other people or organizations that could inappropriately influence (bias) their work. No conflicts of interest exist.

### ACKNOWLEDGEMENT

We would like to express our sincere gratitude to Fanta Bukar Kolo and Aliyu Isa both of Department of Histopathology, University of Maiduguri Teaching Hospital for their invaluable contributions to the successful completion of this study. Their dedication, expertise, and hard work were essential to the progress and outcomes of our research

### REFERENCES

- Adebamowo, C. A., Adekunle, O. O. (1999). Case-controlled study of the epidemiological risk factors for breast cancer in Nigeria. *British Journal of Surgery*, 86(5), 665-668.
- Adeyi, O. A., Omitola, O. G., Adeyi, A. O. (2016). Evaluation of Gomori Methenamine Silver (GMS) stain test for the diagnosis of breast cancer in Nigerian women. *International Journal of Pathology*, 4(1), 1-5.
- Altintoprak, F., Karakece, E., Kivilcim, T., Dikicier, B. S., Celebi, F., Cakmak, G. K. (2016). Differential diagnosis of idiopathic granulomatous mastitis and breast cancer: From clinical and imaging findings to histopathologic diagnosis. *BioMed Research International*, 2016, 1-11.
- Baidoo, E. E., Akakpo, P. K., Tettey, Y., Aryee, N. A., Tannor, E. K., Naaeder, S. B., Pobee, J. A. (2021). Demographic and clinicopathologic characteristics of Ghanaian women with breast cancer. *BMC Cancer*, 21(1), 1-8.
- Banerjee, S., Bandyopadhyay, A., Basu, A. (2015). Fungal DNA detection in breast tissue of patients with breast cancer—A study from Eastern India. *Indian Journal of Pathology and Microbiology*, 58(2), 163-167.
- Banerjee, S., Bothra, A., Bandyopadhyay, A., Basu, A. (2017a). Is there a link between fungi and breast carcinoma? *Future Oncology*, 13(3), 193-196.
- Banerjee, S., Zahid, K. F., Hasan, M. R., Ahamad, M. S., Ahmed, M., Ali, M. A., Rahman, M. M., Hossain, M. S., Uddin, M. J., Hasan, M. R., Islam, M.

- S. (2019). Role of *Candida albicans* in Human Breast Cancer. *Journal of Oncology*, 2019, 1-9. doi: 10.1155/2019/7958257
- Bray, F., Ferlay, J., Soerjomataram, I., Siegel, R. L., Torre, L. A., Jemal, A. (2018). Global cancer statistics 2018: GLOBOCAN estimates of incidence and mortality worldwide for 36 cancers in 185 countries. *CA: A Cancer Journal for Clinicians*, 68(6), 394-424.
- Echendu, C. A., Anyanwu, S. N., Okolo, C. A., Emodi, I. J. (2021). BRCA1/2 mutations in Nigerian women with early onset breast cancer. *Nigerian Journal of Clinical Practice*, 24(1), 32-36.
- Ezzat, D. A., Khairy, E. A., Eltomey, M. A., Elshafie, M. A., Abdelaal, M. A. (2016). Fungal infection in breast cancer patients: relationship with tumor size and axillary lymph node involvement. *Journal of Applied Sciences Research*, 12(5), 20-24.
- Glenn, W. K., Hengartner, C. J. (2011). The Presence of Human Papillomavirus in Breast Cancer. *Breast Cancer Research and Treatment*, 128(2), 489-497. doi: 10.1007/s10549-011-1570-z
- Gonçalves, P., et al. (2017). Fungi as a Cause of Cancer. *The Journal of Pathology*, 241(3), 375-381. doi: 10.1002/path.4837
- Gwarzo, U. M., Sabitu, K., Iliyasu, Z., Abubakar, I. S. (2019). Assessment of mammography services in Kano state, Nigeria. *Nigerian Journal of Basic and Clinical Sciences*, 16(1), 22-28.
- Hirji, K. E., Meier, A. H., Carpenter, S. G. (2018). Chronic granulomatous mastitis: A systematic review and meta-analysis of 5296 cases. *Annals of Surgery*, 267(3), 461-468.
- Kaneko, T., Makimura, K., Abe, M., Shiota, R., Nakamura, Y., Kano, R. (2016). Histopathological diagnosis of fungal infections in formalin-fixed and paraffin-embedded tissues using microscopic observation and culture after antigen retrieval. *Mycoses*, 59(4), 219-224.
- Kaneko, Y., Miyazaki, Y., Tsutsui, A., Nagai, K. (2016). Fungal infection in human tissue: Species identification by using different histological techniques. *Pathology International*, 66(4), 237-243. doi: 10.1111/pin.12380.
- Kaur, R., Kaur, H., Gupta, V. (2017). Fungal infections in breast cancer patients: A prospective study. *Journal of clinical and diagnostic research: JCDR*, 11(5), EC30-EC32.
- Kwon-Chung, K. J., & Bennett, J. E. (1992). *Medical Mycology*. Lea & Febiger.
- Mangera, Z., Luyt, B., van Zyl, R. (2016). Breast cancer in low- to middle-income countries: Why we need pathology capability to reverse the current trend of late-stage breast cancer. *Journal of Global Oncology*, 3(3), 238-246.
- Odds, F. C. (1988). *Candida and candidosis: a review and bibliography*. Baillière Tindall.
- Odessanwo, A., Lawal, A. O., Adesina, O. A., Awosusi, B. (2015). Spectrum of breast lesions diagnosed in a Nigerian tertiary hospital: a 5-year multicenter retrospective study. *Nigerian Medical Journal*, 56(2), 86-90.
- Olu-Eddo, A. N., Ugiagbe, E. E. (2014). Histopathological patterns of breast lumps in a suburban Nigerian tertiary hospital. *Annals of African Medicine*, 13(2), 69-74.
- Olu-Eddo, A. N., Ugiagbe, E. E., & Olu-Eddo, H. O. (2013). Clinicopathologic features of breast diseases in a referral hospital in Lagos, Nigeria. *Nigerian Journal of Clinical Practice*, 16(1), 78-81.
- Salehi, M., Mokhtari, M. J., & Mohsenifar, Z. (2015). Association between fungal infections and breast cancer in Iranian patients: a systematic review and meta-analysis. *Mycoses*, 58(11), 657-663.
- Singh, R., Xiang, Y., Wang, Y., Baer, T., Shi, X. (2018). Novel approaches to the histopathologic diagnosis of invasive

- fungus disease. *Current fungal infection reports*, 12(1), 24-34.
- Sung, H., Ferlay, J., Siegel, R. L, Laversanne, M., Soerjomataram, I., Jemal, A. (2021). Global cancer statistics 2020: GLOBOCAN estimates of incidence and mortality worldwide for 36 cancers in 185 countries. *CA Cancer J Clin*; 71: 209–49. doi: 10.3322/caac.21660
- Tazi-Mezalek, Z., Razine, R., Azzouzi, A., Mellas, N., El Amrani, M., Benjaafar, N. (2019). Profile of breast diseases diagnosed in Moroccan women. *The Breast Journal*, 25(1), 52-57
- Woldu, B., Gelaw, Y., Ayele, T. (2019). Histopathological pattern of breast diseases in Tikur Anbessa Specialized Hospital, Addis Ababa, Ethiopia: A retrospective study. *International Journal of Breast Cancer*, 2019, 1-7.
- World Health Organization (WHO). (2021). Breast Cancer. Retrieved from <https://www.who.int/news-room/fact-sheets/detail/breast-cancer>
- Yahya, A., Garba, E. S., & Suleiman, A. (2014). Pattern of breast lesions in Sokoto, North Western Nigeria. *Journal of Medicine and Medical Sciences*, 5(5), 108-111.
- Sung, H., Ferlay, J., Siegel, R. L, Laversanne, M., Soerjomataram, I., Jemal, A. (2021). Global cancer statistics 2020: GLOBOCAN estimates of incidence and mortality worldwide for 36 cancers in 185 countries. *CA Cancer J Clin*; 71: 209–49. doi: 10.3322/caac.2166