



Research Article

Biochemical and Histochemical Assessment of the Protective Effects of Aqueous and Ethanol Fruit Extracts of Phoenix Dactylifera on Mercury-Induced Liver Toxicity

^{1,2}*MG Abubakar, ¹AN Agbon, ³NI Dibal, and ⁴HY Hassan

¹Microscopy and Stereology Research Unit, Department of Human Anatomy, Ahmadu Bello University, Zaria, Nigeria

²Nigerian Defence Academy, Kaduna, Nigeria

³Department of Human Anatomy, Faculty of Medicine, University of Maiduguri, Borno, Nigeria

⁴Department of Science Education, Faculty of Education, Ahmadu Bello University, Zaria, Nigeria

*Corresponding author's Email: wellorganised@yahoo.com, doi.org/10.55639/607.373635

ARTICLE INFO:

ABSTRACT

Keywords:

Histochemical,
Silymarin,
Oxidative stress,
hepatotoxicity

Mercury is a highly toxic metal that can severely damage the body systems of humans and animals. Date palm (*Phoenix dactylifera*) fruits have various pharmacological properties and are used in traditional medicine globally. This study aimed to evaluate the protective effects of aqueous and ethanol extracts of *Phoenix dactylifera* fruits on mercury-induced liver damage in Wistar rats. Forty-five male Wistar rats were divided into nine groups of five. The control group received distilled water; another group was given only mercury chloride (HgCl_2). A third group was pretreated with silymarin before HgCl_2 exposure. Groups IV and V were pretreated with aqueous extracts of *Phoenix dactylifera* (AFPD) at 500 mg/kg and 1000 mg/kg, respectively, before HgCl_2 exposure. Groups VI and VII received ethanol extracts (EFPD) at similar dosages before HgCl_2 exposure. Groups VIII and IX were treated with AFPD and EFPD only at 1000 mg/kg. After two weeks, the rats were sacrificed, and blood and liver samples were collected for biochemical and histochemical analyses. The study found that mercury induced toxicity and oxidative stress, shown by significantly increased levels of liver enzymes (ALP, AST, ALT) and oxidative markers (MDA). Histochemical analysis showed severe liver damage in the mercury-treated group. However, pretreatment with both AFPD and EFPD extracts preserved liver enzyme activities and antioxidant levels, similar to the control group. The extracts also reduced oxidative stress and preserved liver structure. These protective effects are likely due to the antioxidant properties of the phytochemicals in the extracts, such as flavonoids and tannins.

Corresponding author: MG Abubakar, Email: wellorganised@yahoo.com
Nigerian Defence Academy, Kaduna, Nigeria

INTRODUCTION

Mercury is a widespread environmental and industrial pollutant that exerts toxic effects on a variety of vital organs in humans and animals; it induces severe alterations in tissues [Wadaan *et al.*, 2009; Xu *et al.* 2012]. Mercury will cause severe disruption to any tissue it comes into contact with in sufficient concentration. The liver is an organ that suffer significant damage caused by inorganic mercury such as mercuric chloride [Hounkpatin *et al.*, 2017]. Mercury poisoning can result from inhalation, ingestion, or absorption through the skin and may be highly toxic and corrosive once absorbed into the bloodstream [Wadaan *et al.*, 2009].

Despite massive efforts in search of new drugs that could counteract mercurial toxicity, there is no effective treatment available that can completely abolish its toxic effects. The use of chelating agents assists the body's ability to eliminate mercury from the tissues (Carvalho *et al.*, 2007). However, these chelants are of limited use, because of their adverse side effects (Tchounwou *et al.*, 2003). As a result, the need to evaluate plants for their medicinal activities is of paramount importance.

Date palm (*Phoenix dactylifera*) fruit is a good source of energy, vitamins such as vitamin A, vitamin B6 (pyridoxine), vitamin K, and a group of elements like phosphorus, iron, potassium, and a significant amount of calcium [Hafiz *et al.*, 1980; El Gazzer *et al.*, 2009]. Dates are widely used in traditional medicine for the treatment of various disorders e.g., memory disturbances, fever, inflammation, paralysis, loss of consciousness, and nervous disorders (Nadkarmi, 1976). It is also used in the treatment of sore throat, to relieve fever, cystitis, gonorrhoea, edema, liver and abdominal troubles, and to counteract alcohol intoxication (Barh and Mazumdar, 2008; Al Daihan and Bhat, 2012). The World Health Organization (WHO) estimates that up to 80% of the world's population relies on

traditional medicinal systems for some aspect of primary health care (Farnsworth *et al.*, 1985).

Many pharmacological studies have been conducted on *Phoenix dactylifera* and it has been demonstrated to have antiulcer activity; anticancer activity; anti-diarrhoeal activity; hepatoprotective activity; antimutagenic activity; anti-inflammatory activity; *in vitro* antiviral activity; effect on reproductive system; antihyperlipidemic activity; nephroprotective activity and antioxidant activity (Vyawahare, 2009). Several researchers have also documented the antioxidant properties of *Phoenix dactylifera* (Al-Qarawi, 2008; Wahab, 2010).

MATERIALS AND METHODS

Plant Material Collection and Identification

Dried *Phoenix dactylifera* L. fruits were obtained and authenticated in the Herbarium Unit of Department of Biological Sciences, Faculty of Sciences, Ahmadu Bello University Zaria, Kaduna State, Nigeria where the Voucher Specimen Number, 7130, was obtained.

Experimental Animals

A total of forty-five (45) male Wistar rats (80 to 125 g) were obtained from the Department of Pharmacology animal house, Faculty of Pharmaceutical sciences, Ahmadu Bello University Zaria, Kaduna, Nigeria. Animals were housed in the animal house of the Department of Human Anatomy, Faculty of Medicine, Ahmadu Bello University, Zaria, where they were acclimatized for two weeks prior to the commencement of the experiments. The animals fed on rat chow and water allowed *ad libitum*. They were also kept under standard laboratory conditions: $37^{\circ}\text{C} \pm 2^{\circ}\text{C}$ room temperature and 12 hours light – dark cycles.

In addition, the rats were administered aqueous or ethanol fruit extract of *P. dactylifera*/mercury/silymarin. Rats were weighed at the beginning, during and at the end of the study.

Drugs

Mercury

Seventy grams of mercuric chloride was obtained and used to induce hepatotoxicity for the

experiment. The product was manufactured by British Drug Houses (BDH) chemicals, Poole, England. Batch number- 291634U

Silymarin

Silymarin was used as the standard antioxidant drug for the experiment. Each tablet is film coated and contains 140 mg of silymarin. The product was manufactured by Micro Labs Limited 92, Sipcot, Hosur-635 126, India. Batch number- SYFH0011

Animal Feed

Pelletized Vital Feed was obtained and used to feed the animals for the experiment. The product was manufactured by Grand Cereals and Oil Mills Limited (GCOML), Km 17, Zawan Roundabout, Plateau State, Nigeria; RC 54291.

Plant Extraction

Preparation of aqueous and ethanol fruit extracts of *P. dactylifera* were conducted in the Department of Pharmacognosy, Faculty of Pharmaceutical Sciences, Ahmadu Bello University, Zaria, Kaduna, Nigeria. The maceration methods of Abdul-Wahab *et al.*, 2010 and Agbon *et al.*, 2013 were used for the preparation of the aqueous and ethanol fruit extract of *P. dactylifera* respectively.

Phoenix dactylifera Phytochemical Screening

Phytochemical screening of aqueous and ethanol fruit extracts of *P. dactylifera* were done in the Department of Pharmacognosy, Faculty of Pharmaceutical Sciences, Ahmadu Bello

University, Zaria, Kaduna, Nigeria. The method of Trease and Evans, 2002 was adopted for phytochemical screening.

Experimental design

Forty-five (45) Wistar rats of male sex were divided randomly into common groups (consisting of Groups; I-III) and treatment groups (consisting of Groups IV-IX) having five rats each. Group I served as control and was administered distilled water at 2 ml/kg. Hepatotoxicity was induced by HgCl₂ administration. Group II was administered 5 mg/kg of HgCl₂; 12.5% LD₅₀; 40 mg/kg - Sheikh *et al.*, 2013) only. Group III was administered 100 mg/kg of Silymarin as reported by Ahmed *et al.*, 2016 followed by 5 mg/kg of HgCl₂. Groups IV was administered 500mg/kg of aqueous fruit extract of *P. dactylifera* followed by 5 mg/kg of HgCl₂. Group V was administered 1000 mg/kg of aqueous fruit extract of *P. dactylifera* followed by HgCl₂ at 5 mg/kg. Groups VI was administered 500 mg/kg of ethanol fruit extract of *P. dactylifera* followed by HgCl₂ at 5 mg/kg. Group VII was administered 1000 mg/kg of ethanol fruit extract of *P. dactylifera* followed by 5 mg/kg of HgCl₂. Groups VIII was administered 1000 mg/kg of aqueous fruit extract of *P. dactylifera* only while Group IX was administered 1000 mg/kg of ethanol fruit extract of *P. dactylifera* only. The administrations were orally done and lasted for a period of 2 weeks as shown in Table 1.

Table 1: Treatment of Experimental Animals

Group	Treatment/ daily	Duration
I	Distilled water (2 ml/kg)	2 weeks
II	HgCl ₂ (5 mg/kg)	2 weeks
III	Silymarin (100 mg/kg) + HgCl ₂ (5 mg/kg)	2 weeks
IV	AFPD (500 mg/kg) + HgCl ₂ (5 mg/kg)	2 weeks
V	AFPD (1,000 mg/kg) + HgCl ₂ (5 mg/kg)	2 weeks
VI	EFPD (500 mg/kg) + HgCl ₂ (5 mg/kg)	2 weeks
VII	EFPD (1000 mg/kg) + HgCl ₂ (5mg/kg)	2 weeks
VIII	AFPD (1000 mg/kg) only	2 weeks
IX	EFPD (1000 mg/kg) only	2 weeks

Note: Treatments were administrations orally. Mercuric chloride (HgCl₂); aqueous fruit extract of *P. dactylifera* (AFPD), ethanol fruit extract of *P. dactylifera* (EFPD).

Animal Sacrifice

At the end of the experiment, the rats were humanely sacrificed under chloroform anesthesia. The rats were dissected, blood samples were collected with the use of sample bottles and the kidney was excised, weighed and fixed in 10% formal saline.

Biochemical Studies

Biochemical studies were carried out using the collected blood samples in the Department of Chemical Pathology, Faculty of Medicine, Ahmadu Bello University Teaching Hospital, Shika. Biochemical analysis for liver serum markers namely Alanine transaminase-ALT, Alkaline phosphatase- ALP and Aspartate aminotransferase- AST; and antioxidant enzyme activity namely malondialdehyde - MDA, superoxide dismutase - SOD, catalase - CAT and glutathione peroxidase - GSHPx were performed.

Histochemical Studies

At the end of the experiment, harvested liver organs were fixed in 10% formal saline and tissues were processed for histochemical (Godon and Sweet for demonstrating reticular fibers) analysis. Micrographs were examined under the light microscope.

NOTE: All groups' names/numbers were concealed/blinded prior to the commencement of the biochemical and histochemical analyses to eliminate bias. Codes only known to the authors were allotted to each group for identification purposes.

RESULTS**Phytochemical Analyses**

Phytochemical analyses of aqueous and ethanol fruit extracts of *Phoenix dactylifera* indicating the presence of secondary metabolites is as shown in Table 2.

Table 2: Phytochemical constituents of Aqueous and Ethanol extracts of *Phoenix dactylifera*

Constituents	Aqueous extract	Ethanol extract
	Inference	Inference
Anthraquinones	–	–
Cardiac glycosides	–	–
Saponins	+	+
Flavonoids	+	+
Tannins	+	+
Alkaloids	+	+

+ = Positive (present)

– = Negative (absent)

The table above shows the result of the qualitative phytochemical screening of aqueous and ethanol fruit extracts of *Phoenix dactylifera*. The negative sign indicates the absence of a phytochemical constituents while the positive

sign indicates the presence of the phytochemical.

Biochemical Studies

Biochemical studies involved the analyses of serum liver enzymes, lipid peroxidation and

antioxidant enzyme activities of the experimental animals.

Liver Serum Enzymes

The analysis of liver serum enzymes revealed increased levels of AST and ALT enzymes in the HgCl₂ treated group when compared to the control while other treatment groups revealed a

decrease in these enzymes when compared to the HgCl₂ treated group. However, these changes were not significant as seen in figures 1 and 2. ALP levels increased significant ($p < 0.05$) in groups II, IV, VI and IX when compared to the control group as shown in Figure 3.

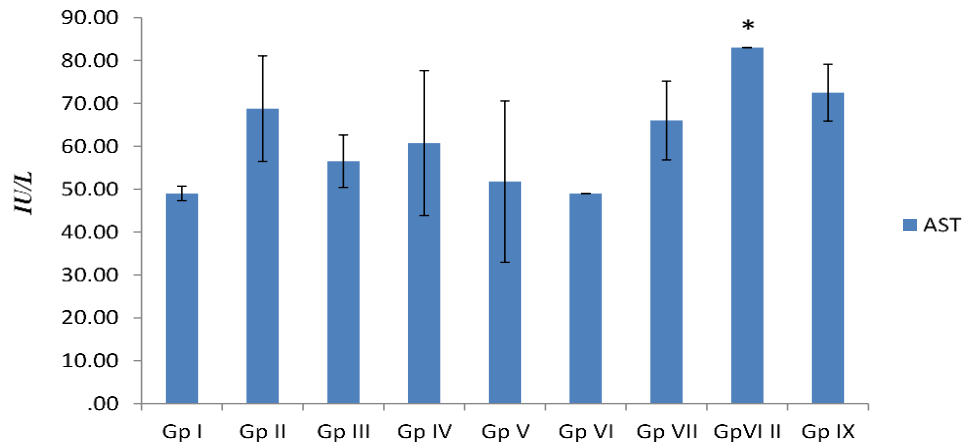


Figure 1: Effect of fruit extracts of *P.dactylifera* on Aspartate Transaminase (AST) against mercury-induced liver toxicity in Wistar rats n=5, values are mean ± SEM. * = $p < 0.05$; significant difference when Gp VIII was compared with the control. **Gp I**=Control (distilled H₂O 0.5 ml/kg); **II**=HgCl₂ (5 mg/kg); **III**= Silymarin (100mg/kg); **IV and V**=Aqueous fruit extract of *P.dactylifera* (500 and 1,000 mg/kg respectively); **VI and VII**= Ethanol fruit extract of *P.dactylifera* (500 and 1,000 mg/kg respectively); **VIII**=aqueous fruit extract of *P.dactylifera* (1,000 mg/kg); **IX**= Ethanol fruit extract of *P.dactylifera* (1,000 mg/kg).

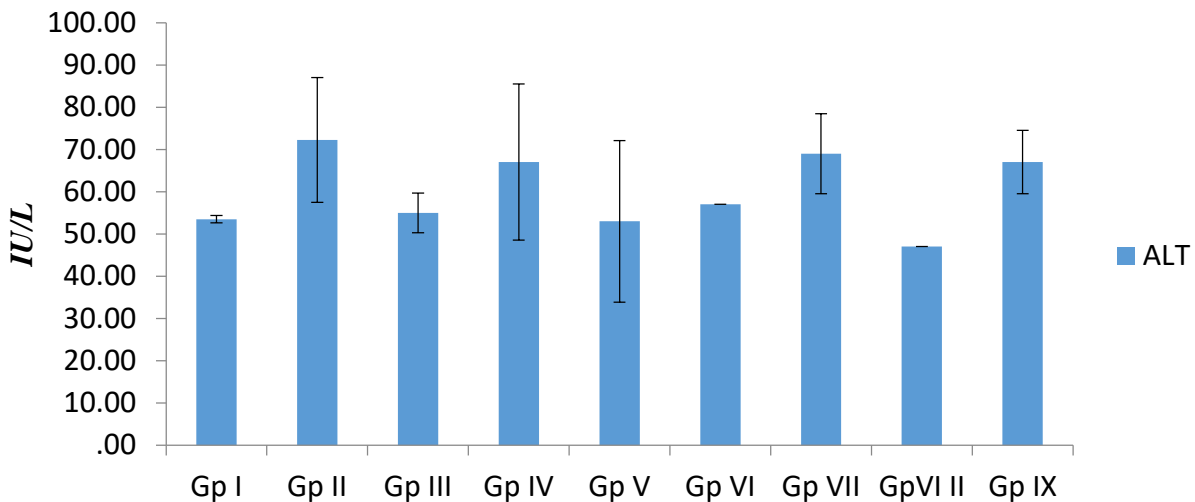


Figure 2: Effect of fruit extracts of *P.dactylifera* on Alanine Transaminase (ALT) against mercury-induced liver toxicity in Wistar rats

n=5, values are mean \pm SEM. $P > 0.05$; when comparison was carried out across the groups. **Gp I**=Control (distilled H₂O 0.5 ml/kg); **II**=HgCl₂ (5 mg/kg); **III**= Silymarin (100mg/kg); **IV and V**=Aqueous fruit extract of *P.dactylifera* (500 and 1,000 mg/kg respectively); **VI and VII**=Ethanol fruit extract of *P.dactylifera* (500 and 1,000 mg/kg respectively); **VIII** =aqueous fruit extract of *P.dactylifera* (1,000 mg/kg); **IX** Ethanol fruit extract of *P.dactylifera* (1,000 mg/kg).

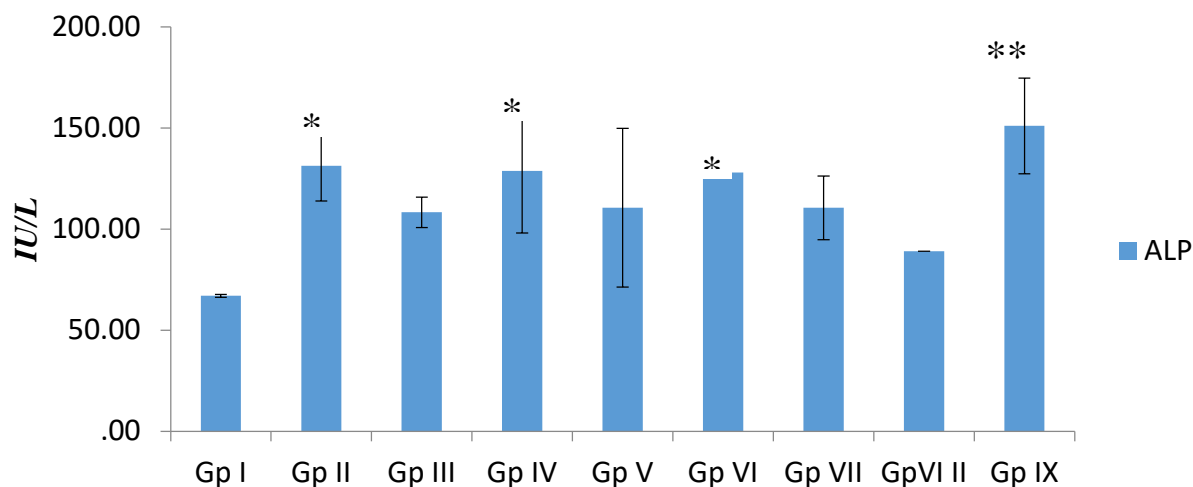


Figure 3: Effect of fruit extracts of *P.dactylifera* on Alkaline Phosphatase (ALP) against mercury-induced liver toxicity in Wistar rats

n=5, values are mean \pm SEM. * = $p < 0.05$; ** = $p < 0.01$; significant difference when groups II, IV, VI & IX were compared to the control. **Gp I**=Control (distilled H₂O 0.5 ml/kg); **II**= HgCl₂ (5 mg/kg); **III**= Silymarin (100mg/kg); **IV and V**=Aqueous fruit extract of *P.dactylifera* (500 and 1,000 mg/kg respectively); **VI and VII**= Ethanol fruit extract of *P.dactylifera* (500 and 1,000 mg/kg respectively); **VIII**=aqueous fruit extract of *P.dactylifera* (1,000 mg/kg); **IX**=Ethanol fruit extract of *P.dactylifera* (1,000 mg/kg).

Lipid Peroxide Levels and Antioxidant Enzyme Activity

The malondialdehyde (MDA) or thiobarbituric acid-reactive-substances (TBARS) assay was used to estimate lipid peroxidation levels which is a marker of lipid peroxidation, while antioxidant enzymatic activity was estimated by assaying for superoxide dismutase (SOD), catalase (CAT) and glutathione peroxidase (GPx) activities using the serum of the rats.

Serum MDA levels increased ($p < 0.05$) in the HgCl₂-treated group when compared to the control group. All other treated groups revealed non-significant changes in MDA as compared to the control. When compared to the HgCl₂-treated group, MDA levels decreased significantly in all the treated Groups as shown in figure 4.

Serum SOD results revealed non-remarkable changes in SOD activity in all the treated groups except in group IV which showed a remarkable increase as compared to the control group. In comparison to the HgCl₂-treated group, SOD activity increased remarkably in group IV as shown in figure 5.

There were no significant changes in serum CAT and GPx activity in all the treated groups when compared to control as well as the HgCl₂-treated group as shown in figures 6 & 7.

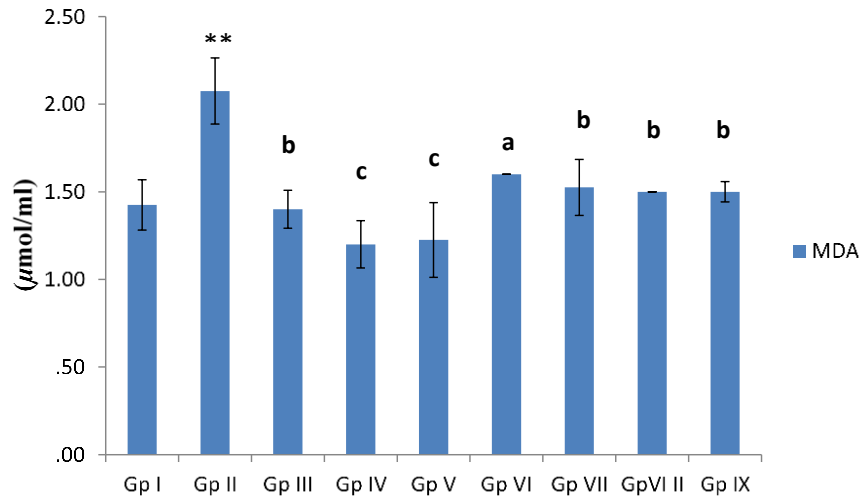


Figure 4: Effect of fruit extracts of *P. dactylifera* on blood serum Malondialdehyde (MDA) concentration of Wistar rats

n=5, values are mean \pm SEM. ** = $p < 0.01$; significant difference when compared with the control; a = $p < 0.05$, b = $p < 0.01$, c = $p < 0.001$; significant difference when compared with the MCL group. **Gp I**=Control (distilled H₂O 0.5 ml/kg); **II**= HgCl₂ (5 mg/kg); **III**= Silymarin (100mg/kg); **IV and V**= Aqueous fruit extract of *P.dactylifera* (500 and 1,000 mg/kg respectively); **VI and VII**= Ethanol fruit extract of *P.dactylifera* (500 and 1,000 mg/kg respectively); **VIII** aqueous fruit extract of *P.dactylifera* (1,000 mg/kg); **IX** Ethanol fruit extract of *P.dactylifera* (1,000 mg/kg).

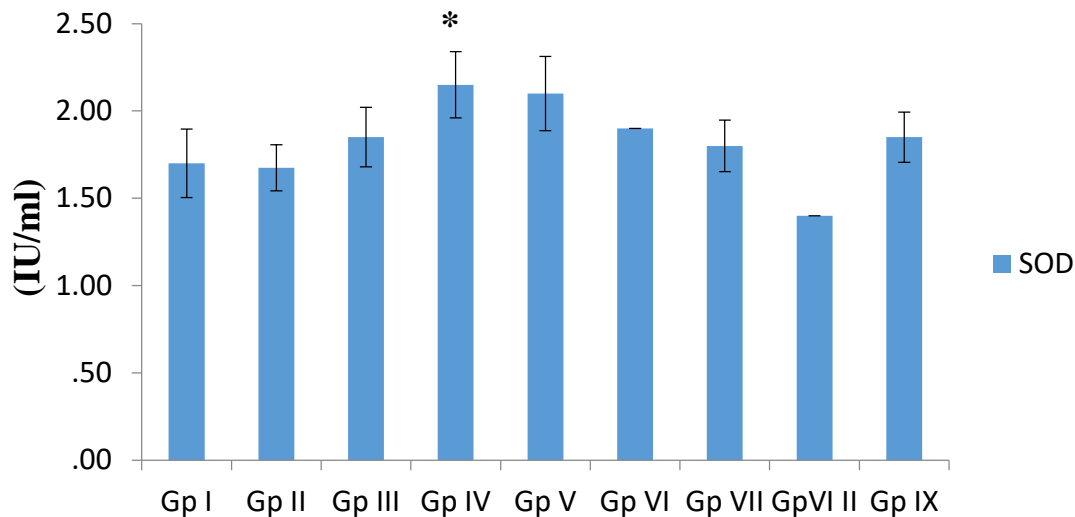


Figure 5: Effect of fruit extracts of *P. dactylifera* on blood serum Superoxide dismutase (SOD) activity of Wistar rats

n=5, values are mean \pm SEM. * = $p < 0.05$; significant difference when compared with the control; a = $p < 0.05$; significant difference when compared with the MCL group. **Gp I**=Control (distilled H₂O 0.5 ml/kg); **II**= HgCl₂ (5 mg/kg); **III**= Silymarin (100mg/kg); **IV and V**= Aqueous fruit extract of *P.dactylifera* (500 and 1,000 mg/kg respectively); **VI and VII**= Ethanol fruit extract of *P.dactylifera* (500 and 1,000 mg/kg respectively); **VIII** aqueous fruit extract of *P.dactylifera* (1,000 mg/kg); **IX** Ethanol fruit extract of *P.dactylifera* (1,000 mg/kg).

respectively); **VIII** aqueous fruit extract of *P.dactylifera* (1,000 mg/kg); **IX** Ethanol fruit extract of *P.dactylifera* (1,000 mg/kg).

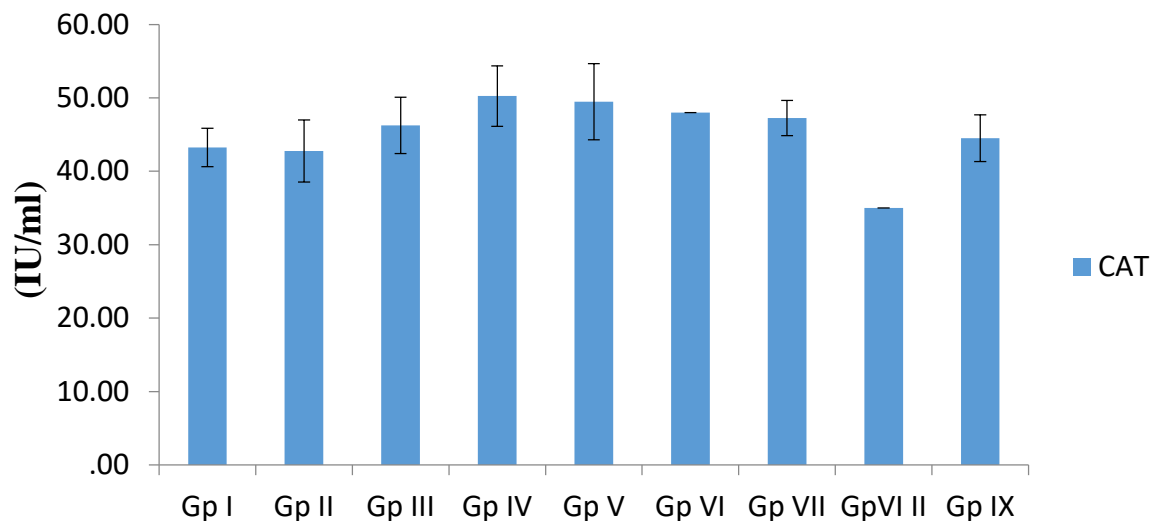


Figure 6: Effect of fruit extracts of *P. dactylifera* on blood serum Catalase (CAT) activity of Wistar rats

n=5, values are mean ± SEM. $P > 0.05$; when compared with the *control*. **Gp I**=Control (distilled H₂O 0.5 ml/kg); **II**= HgCl₂ (5 mg/kg); **III**= Silymarin (100mg/kg); **IV and V**= Aqueous fruit extract of *P.dactylifera* (500 and 1,000 mg/kg respectively); **VI and VII**= Ethanol fruit extract of *P.dactylifera* (500 and 1,000 mg/kg respectively); **VIII** aqueous fruit extract of *P.dactylifera* (1,000 mg/kg); **IX** Ethanol fruit extract of *P.dactylifera* (1,000 mg/kg).

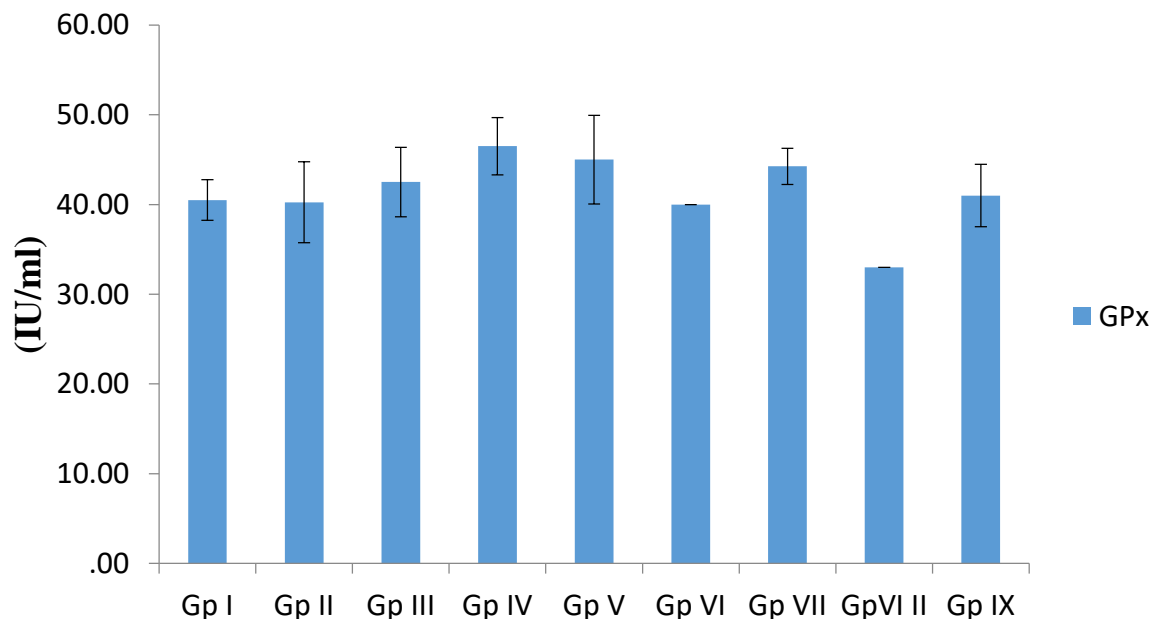


Figure 7: Effect of fruit extracts of *P. dactylifera* on blood serum Glutathione peroxidase (GPx) activity of Wistar rats

n=5, values are mean ± SEM. $P > 0.05$; when compared with the *control*. **Gp I**=Control (distilled H₂O 0.5 ml/kg); **II**= HgCl₂ (5 mg/kg); **III**= Silymarin (100mg/kg); **IV and V**= Aqueous fruit extract of *P.dactylifera* (500 and 1,000 mg/kg respectively); **VI and VII**= Ethanol fruit extract of *P.dactylifera* (500 and 1,000 mg/kg respectively); **VIII** aqueous fruit extract of *P.dactylifera* (1,000 mg/kg); **IX** Ethanol fruit extract of *P.dactylifera* (1,000 mg/kg).

P.dactylifera (500 and 1,000 mg/kg respectively); **VIII** aqueous fruit extract of *P.dactylifera* (1,000 mg/kg); **IX** Ethanol fruit extract of *P.dactylifera* (1,000 mg/kg).

Histopathological Studies of the Liver

Histological sections of Wistar rats’ liver stained with Gordon and Sweet, (GS) were examined under the light microscope and revealed the following:

Histological observation of the liver sections of rats in the control group revealed normal reticulin framework as shown in figure 8, Plate A. In the group treated with HgCl₂, histological observation revealed areas of severe disintegrating of the

reticulin framework when compared to the control as shown in figure 8, Plate B. The silymarin and AFPD-treated groups followed by HgCl₂ showed mild distortion of reticular fibers while the EFPD treated group followed by HgCl₂ was comparable to the control as seen in figure 8, Plate C – G. Histochemical examinations of the liver sections of Wistar rats treated with AFPD and EFPD only was also comparable to the control as shown in figure 8, Plate H & I.

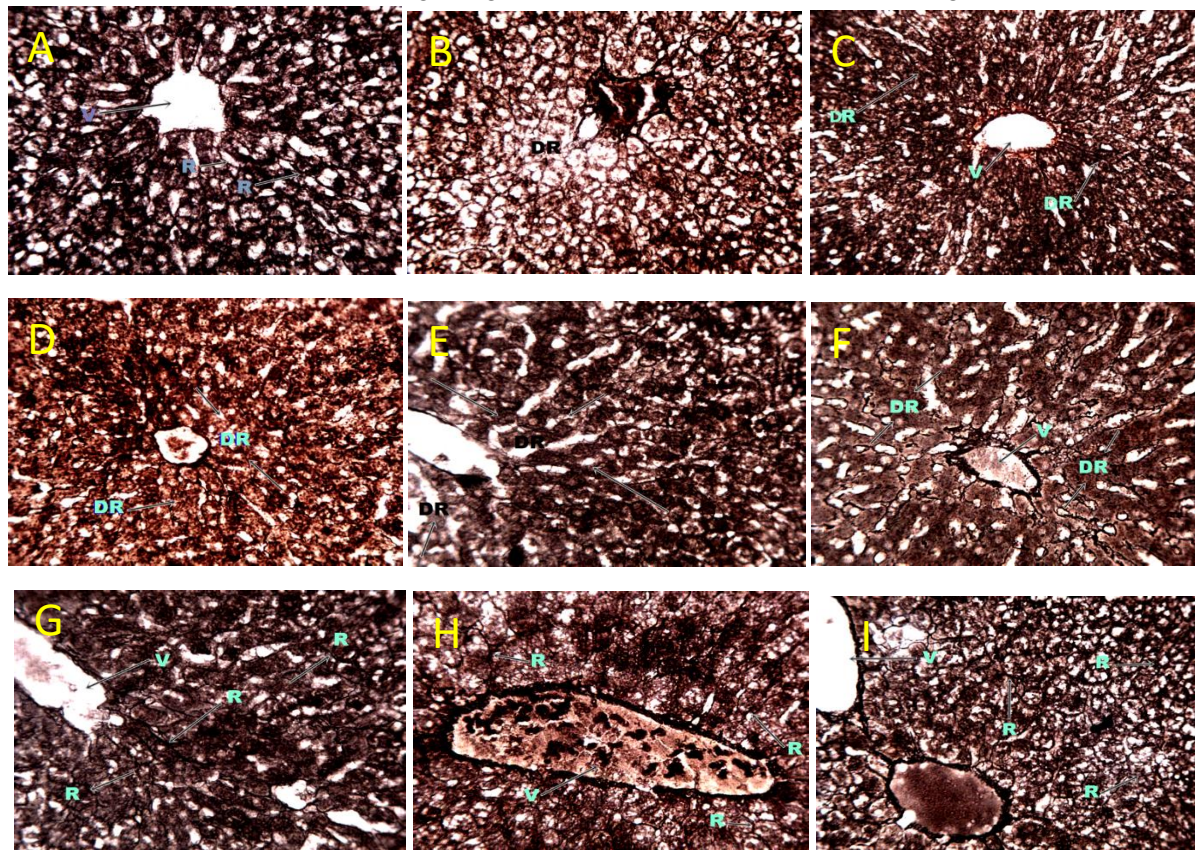


Figure 8: The liver section of Wistar rat (G & S x 250)

Plate A: Photomicrograph of the transverse section of Liver section of Wistar rat of Control Group showing; normal reticular framework (R); Central vein (V). Gordon and Sweet; (Mag x 250).

Plate B: Photomicrograph of the transverse section of Liver section of Wistar rat of Group II

demonstrating area of severe disintegrated reticulin framework (DR). Gordon and Sweet; (Mag x 250).

Plate C: Photomicrograph of the transverse section of Liver section of Wistar rat of Group III demonstrating areas of mildly disoriented

reticulin framework (DR). Central vein (V). Gordon and Sweet; (Mag x250).

Plate D: Photomicrograph of the transverse section of Liver section of Wistar rat of Group IV demonstrating areas of mildly disintegrated reticulin fiber (DR). Gordon and Sweet; (Mag x 250).

Plate E: Photomicrograph of the transverse section of Liver section of Wistar rat of Group V demonstrating areas of mild disintegrated reticulin fibers (DR); Central vein (V). Gordon and Sweet; (Mag x 250).

Plate F: Photomicrograph of the transverse section of Liver section of Wistar rat of Group VI demonstrating mildly disoriented reticulin

framework (DR); Central vein (V). Gordon and Sweet; (Mag x 250)

Plate G: Photomicrograph of the transverse section of Liver section of Wistar rat of Group VII demonstrating normal reticulin framework (R). Central vein (V). Gordon and Sweet; (Mag x250).

Plate H: Photomicrograph of the transverse section of Liver section of Wistar rat of Group VIII demonstrating normal reticulin fibers (DR). Central vein (V). Gordon and Sweet; (Mag x250).

Plate I: Photomicrograph of the transverse section of Liver section of Wistar rat of Group IX demonstrating normal reticulin framework (R); Central vein (V). Gordon and Sweet; (Mag x250).

DISCUSSIONS

In the present study, preliminary phytochemical screening was carried out, and the protective effect of aqueous and ethanol fruit extracts of *Phoenix dactylifera* on mercury-induced liver damage in Wistar rats were investigated using biochemical and histochemical techniques. Phytochemical screening of the plant (*Phoenix dactylifera*) fruit extracts (aqueous and ethanol) revealed the presence of flavonoids, saponins, tannins and alkaloids which have been reported to possess hepatoprotective activities [Abdul Wahab *et al.*, 2010; Saafi-Ben Salah *et al.*, 2012] in animals and cell culture models.

Mercury exposure triggers lipid peroxidation which causes injury to the liver and prevents it from functioning properly (Holland, 2019). According to Wargovich *et al.* (2001) and Kumari and Chand, (2021), mercury chloride is one of the most toxic forms of mercury as it easily forms organomercuric complexes with proteins in an organism. Being the major site of drug metabolism, the liver metabolizes mercury and this results in severe alterations to the organ (Gomez-Lechon *et al.*, 2010).

When there is damage to the liver, cellular enzymes namely AST, ALT and ALP leaks into the blood resulting in the elevation of their serum concentration. The results of the present study revealed that the rats treated with HgCl₂ showed increased blood levels of aspartate aminotransferase (AST), alanine aminotransferase (ALT) and significant increase in alkaline phosphatase (ALP) as compared to the control group. This could be attributed to hepatocellular injury and damage to the plasma membrane as a result of HgCl₂ toxicity. [Uzunhisarcikli *et al.*, 2016; Badr *et al.*, 2019]. Rats that were pretreated with silymarin, AFPD and EFPD followed by HgCl₂ showed a decrease in AST, ALT, and ALP when compared to HgCl₂ treated group. This result indicated that aqueous and ethanol fruit extracts of *P. dactylifera* offer protection against HgCl₂ hepatotoxicity by stabilizing the cell membrane and preventing enzyme leakage. This outcome is supported by previous studies of Al-Qarawi *et al.*, 2008 and Ali *et al.*, 2014. Groups VIII and IX which were treated with only AFPD and EFPD respectively, revealed significant increases in levels of AST and ALP when compared to control group, however, these increases were insignificant when

compared to the HgCl₂ group. The reason for this is unclear and recommended for further studies.

HgCl₂ induces hepatotoxicity through free radical mediation and reactive oxygen species generation which ultimately leads to cell death (Yang *et al.*, 2016). Oral administration of HgCl₂ induced hepatotoxicity as observed by the increase in the levels of oxidative stress biomarkers. Malondialdehyde (MDA) levels significantly increased while the activities of superoxide dismutase (SOD), catalase (CAT) and glutathione peroxidase (GPx) decreased as a result of HgCl₂ exposure. This is a result of the accumulation of toxic metabolites in the system brought about by HgCl₂ induced oxidative stress. The ROS generated by HgCl₂ overwhelms the organic antioxidants in the animals, therefore depleting them. Pretreatment with AFPD and EFPD followed by HgCl₂ significantly decreased the level of MDA and restored (increased) the activities of SOD, CAT and GPx towards normal. Owing to the fact that antioxidants checkmate free radicals and stabilizes them, this indicates that the protective potential of the extracts of *P. dactylifera* could be associated with antioxidant activity aimed against oxidative stress. These findings corroborate the hepatoprotective effect of extracts of *P. dactylifera* against HgCl₂ induced toxicity. This result agrees with previous reports on the hepatoprotective effects of *P. dactylifera* by Saafi-Ben Salah *et al.*, 2012; Ali *et al.*, 2014.

Reticular fibers are a special type of connective tissue that are delicately arranged in a mesh-like manner providing support to the hepatocytes and sinusoids (Rad, 2022). Hence, the reticulin stain provides important information about the structural integrity of the liver. The reticulin network is particularly rich in the liver and can be seen along hepatic sinusoids. In the present study, light microscopic examination of Gordon and Sweet stained histological sections of Wistar rats' liver tissues were carried out. Histochemical results obtained revealed normal reticular

framework in the liver sections obtained from the control, however, sections from the HgCl₂ treated group showed areas of collapsed or disintegrated reticular frame work as a result of HgCl₂ toxicity. HgCl₂ toxicity could lead to necrosis and when hepatocytes are damaged and undergo necrosis, the reticulin fibers surrounding them collapse in the empty space left behind [Saxena, 2011] leaving behind a weak liver parenchyma. This result contradicts the work of Yasir *et al.* (2022) who reported that reticulin loss was not associated with the degree of inflammation or with the presence or absence of alteration in cell change.

As a hepatoprotective agent, silymarin has been used for centuries to treat liver, spleen and gall bladder disorders [Shaker *et al.*, 2010]. The groups administered silymarin, AFPD and EFPD followed by HgCl₂ demonstrated areas of mild disintegration of the reticular fibers when compared to the HgCl₂ treated group. This indicates that the administration of silymarin, AFPD and EFPD ameliorated the sever effect of HgCl₂ toxicity leading to the reduction of necrotic cells. This helped to maintain the reticulin fibers and prevent collapse of the architectural structure of the liver. Treatment of Wistar rats with only AFPD and EFPD revealed normal reticulin framework, an indication of the protective abilities possessed by these extracts of *Phoenix dactylifera*.

CONCLUSION

The result of the present study suggests that, the aqueous and ethanol fruit extracts of *Phoenix dactylifera* possesses the ability to protect against mercury-induced alterations in the liver of Wistar rats. As regards the outcome of this study, the hepatoprotective property of the extracts is comparable to that of the standard drug (silymarin), this may be attributed to the antioxidant properties of the constituent phytochemicals, such as flavonoids. These antioxidants properties exhibited by the extracts of *P. dactylifera* help to scavenge, stabilize and

eliminate ROS by single-electron transfer (Malešev *et al.*, 2007; Procházková *et al.*, 2011). Also, the EFPD seems to have more protective effects when compared to the AFPD. This may be due to the quantity and quality of phytochemicals found in the EFPD owing to the preparation process. Thus, these extracts are potential candidates for use in the management and treatment of ROS-induced liver diseases.

DECLARATIONS

ETHICAL APPROVAL

This experiment complied with the international regulations guiding the use of Animals in biomedical research and experimental design as ethical approval was obtained from Ahmadu Bello University Ethics Committee on the use of

Animals for Research and the number ABUCAUC/2023/067 was allocated to this research work.

FUNDING

This research did not receive any specific grant from funding agencies in the public, commercial, or not-for-profit sectors.

CONFLICT OF INTEREST

There was no conflict of interest between the authors.

ACKNOWLEDGMENTS

The authors wish to acknowledge the Department of Human Anatomy, Faculty of Basic Medical Sciences, Ahmadu Bello University, Zaria, for providing the facilities to conduct this study.

REFERENCES

- Agbon, A. N., Kwaneshie, H. O., & Hamman, W. O. (2013). Antidiarrheal activity of aqueous fruit extract of Phoenix dactylifera (DATE PALM) in Wistar rats. *British Journal of Pharmacology and Toxicology*, 4(3), 121-127.
- Ahmed, A. F., Mahmoud, M. F., Ouf, M. A., & Abd El-Fathaah, E. (2016). Aminoguanidine potentiates the hepatoprotective effect of silymarin in CCL4 treated rats. *Annals of hepatology*, 10(2), 207-215.
- Al-Daihan, S., & Bhat, R. S. (2012). Antibacterial activities of extracts of leaf, fruit, seed and bark of Phoenix dactylifera. *African Journal of Biotechnology*, 11(42), 10021-10025.
- Ali, A., Seyyed, M. K., Mohsen, P., Perham, M., and Hamid, R.S.R., (2014). Effect of Aqueous Extract of Phoenixdactylifera Pollen on Dopamine System of Nucleus Accumbens in Male Rats. *Neuroscience & Medicine*, 5:49-59.
- Al-Qarawi, A. A., Abdel-Rahman, H., Mousa, H. M., Ali, B. H., & El-Mougy, S. A. (2008). Nephroprotective action of Phoenix dactylifera. in gentamicin-induced nephrotoxicity. *Pharmaceutical Biology*, 46(4), 227-230.
- Badr, M. I., Abd El-Hamid A.A., and Abd El-Ghfar, S.S. (2019) "Effects of some medicinal plants on bone formation and bone resorption in normal and diabetic rats." *Archives of Agriculture Sciences Journal* 2, no. 1: 13-27.
- Barh, D., & Mazumdar, B. C. (2008). Comparative nutritive values of palm saps before and after their partial fermentation and effective use of wild date (Phoenix sylvestris Roxb.) sap in treatment of anemia. *Research Journal of Medicine and Medical Sciences*, 3(2), 173-176.
- Carvalho, M. C., Franco, J. L., Ghizoni, H., Kobus, K., Nazari, E. M., Rocha, J. B., ... & Farina, M. (2007). Effects of 2, 3-dimercapto-1-propanesulfonic acid (DMPS) on methylmercury-induced locomotor deficits and cerebellar toxicity in mice. *Toxicology*, 239(3), 195-203.
- El-Gazzar, U. B., & El-Far, A. H. (2009). The ameliorative effect of Phoenix dactylifera extract on CCl4 hepatotoxicity in New Zealand rabbits. *Journal of Applied Sciences Research*, (September), 1082-1087.
- Farnsworth, N. R., Akerele, O., & Bingel, A. S. (1987). Medicinal plants in

- therapy. *Journal of Ethnopharmacology*, 19(3), 336.
- Hafiz, M. A., Shalabi, A. F., & Akhal, I. A. (1980). Chemical composition of 15 varieties of dates grown in Saudi Arabia. In *Proceedings of the Fourth Conference on the Biological Aspects of Saudi Arabia* University of Riyadh.
- Hounkpatin, A. S., Roch, C., Senou, M., Dovonon, L., Chibuisi, G., Alimba, S. G., ... & GLITHO, I. (2017). Protective effects of vitamin C on kidney, liver and brain: a study in wistar rats intoxicated with mercury. *Ann. UP Série Sci. Nat. Agron*, 7, 168-177.
- Kumari, K. and Chand, G.B. (2021). Acute toxicity assessment of mercury chloride to freshwater air breathing fish *Claesius batrachus* (Linnaeus, 1758): In vivo study. *Agricultural Science Digest Research Journal*, 41: 242-246.
- Malešev, D., Kuntić, V. (2007). Investigation of metal-flavonoid chelates and the determination of flavonoids via metal-flavonoid complexing reactions. *Journal of the Serbian chemical society*.72(10):921-39.
- Mohamed, D. A., & Al-Okbi, S. Y. (2005). In vitro evaluation of antioxidant activity of different extracts of *Phoenix dactylifera* L. fruits as functional foods.
- Nadkarmi, K. M. *Indian Materia Medica* Vol 1. 1976 Mumbai, Bombay Popular Prakashan Pvt.
- Procházková, D., Boušová, I., Wilhelmová, N. (2011). Antioxidant and prooxidant properties of flavonoids. *Fitoterapia*. Jun 1;82(4):513-23.
- Rad, A. Reticular connective tissue. Last reviewed: June 29, 2022. Reticular tissue histology | Kenhub.
- Saafi-Ben Salah, E. B., El Arem, A., Louedi, M., Saoudi, M., Elfeki, A., Zakhama, A., ... & Achour, L. (2012). Antioxidant-rich date palm fruit extract inhibits oxidative stress and nephrotoxicity induced by dimethoate in rat. *Journal of physiology and biochemistry*, 68, 47-58.
- Saxena, R. (2011). Nonneoplastic Hepatobiliary Disease. *Essentials of Anatomic Pathology*, 1771-1827.
- Shaker, E., Mahmoud, H., & Mnaa, S. (2010). Silymarin, the antioxidant component and *Silybum marianum* extracts prevent liver damage. *Food and Chemical Toxicology*, 48(3), 803-806.
- Sheikh, T. J., Patel, B. J., Joshi, D. V., Patel, R. B., & Jegoda, M. D. (2013). Repeated dose oral toxicity of inorganic mercury in wistar rats: biochemical and morphological alterations. *Veterinary World*, 6(8).
- Tchounwou, P. B., Ayensu, W. K., Ninashvili, N., & Sutton, D. (2003). Environmental exposure to mercury and its toxicopathologic implications for public health. *Environmental Toxicology: An International Journal*, 18(3), 149-175.
- Trease, G.E. and Evans, W.C. (2002). Phytochemicals. In: *Pharmacognosy*. 15: 42-393.
- Uzunhisarcikli, M., Aslanturk, A., Kalender, S., Apaydin, F. G., & Bas, H. (2016). Mercuric chloride induced hepatotoxic and hematologic changes in rats: The protective effects of sodium selenite and vitamin E. *Toxicology and industrial health*, 32(9), 1651-1662.
- Vyawahare, N., Pujari, R., & Khsirsagar, A. (2009). *Phoenix dactylifera*: An update of its indigenous uses, phytochemistry and pharmacology.
- Wadaan, M. A. (2009). Effects of mercury exposure on blood chemistry and liver histopathology of male rats. *Journal of Pharmacology and Toxicology*, 4(3), 126-131.
- Wahab, A. A., Mabrouk, M. A. A., Joro, J. M., Oluwatobi, S. E., Bauchi, Z. M., & John, A. A. (2010). Ethanolic extract of *Phoenix dactylifera* L. prevents lead induced hematotoxicity in rats. *Cont. J. Biomed. Sci*, 4, 10-15.
- Wargovich, M. J., Woods, C., Hollis, D. M., & Zander, M. E. (2001). Herbs, cancer prevention and health. *The Journal of nutrition*, 131(11), 3034S-3036S.
- Xu, F., Farkas, S., Kortbeek, S., Zhang, F. X., Chen, L., Zamponi, G. W., & Syed, N. I. (2012). Mercury-induced toxicity of rat cortical neurons is mediated through N-

- methyl-D-Aspartate receptors. *Molecular brain*, 5, 1-14.
- Yasir, S., Chen, Z.E., Jain, D., Kakar, S., Wu, T.T., Yeh, M.M., and Torbenson, M.S. (2022). Hepatic adenomas in patients 60 and older are enriched for HNF1A inactivation and malignant transformation. *American Journal of Surgical Pathology*. 46(6): 786-792.
- Yang, D., Tan, X., Lv, Z., Liu, B., Baiyun, R., Lu, J., and Zhang, Z. (2016). Regulation of Sirt1/Nrf2/ TNF- α signaling pathway by luteolin is critical to attenuate acute mercuric chloride exposure induced hepatotoxicity. *Science Report*, 6: 37157.