



Research Article

Management of Canine Parvoviral Enteritis in a 7-Month-Old Male Caucasian Dog: A case report

Muhammad Mustapha<sup>\*1,4</sup>, Sulayman Tunde Balogun<sup>2,5</sup>, Nicholas Nathaniel Pilau<sup>3,4</sup>,

<sup>1</sup>Department of Veterinary Medicine, Faculty of Veterinary Medicine, University of Maiduguri, Nigeria

<sup>2</sup>Department of Clinical Pharmacology and Therapeutics, Faculty of Basic Clinical Sciences, College of Medical Sciences, University of Maiduguri, Nigeria

<sup>3</sup>Department of Veterinary Medicine, Faculty of Veterinary Medicine, Usmanu Danfodiyo University Sokoto, Sokoto, Nigeria

<sup>4</sup>Small Animal Medicine Option, Faculty of Medicine and Pharmacy, College of Veterinary Surgeons, Nigeria

<sup>5</sup>Clinical Pharmacology and Toxicology Option, Faculty of Medicine and Pharmacy, College of Veterinary Surgeons, Nigeria

\*Corresponding author's Email: [tanimuzimbos@gmail.com](mailto:tanimuzimbos@gmail.com), [doi.org/10.55639/607.02010017](https://doi.org/10.55639/607.02010017)

ARTICLE INFO:

ABSTRACT

**Keywords:**

Parvoviral Enteritis,  
Canine,  
Diagnosis,  
Treatment

A 7 months dog (Bruno) weighing 20kg was presented to Small Animal Clinic of Veterinary Teaching Hospital, University of Maiduguri with the chief complaints of progressive weakness, passing out bloody diarrhea that later became mucoid, with vomiting, and inappetence. The temperature (40.1°C), pulse rate (70 beat per minute, and the respiratory rate (80 cycle per minute). The mucous membrane was slightly pale, anorexia, depression, pyrexia, vomiting and profuse foul smelling bloody diarrhea. History has it that the Dog was vaccinated with one shot of DHLPP vaccine only at five weeks. Using a commercially available parvoviral antigen fast test kit (Bionote)<sup>®</sup>, a puppy fecal sample tested positive for canine parvoviral enteritis. The dog was hospitalized for one week to treat the disease condition, and after three weeks, it was released and vaccinated. The owner received thorough guidance on the significance of following vaccination schedules, deworming procedures, and keeping the surroundings clean in order to prevent reinfection. To reduce the possibility of parvoviral outbreaks, special attention was paid to separating new puppies and making sure that stringent biosecurity protocols were followed.

**Corresponding author:** Muhammad Mustapha, **Email:** [tanimuzimbos@gmail.com](mailto:tanimuzimbos@gmail.com)  
Department of Veterinary Medicine, Faculty of Veterinary Medicine, University of Maiduguri, Nigeria

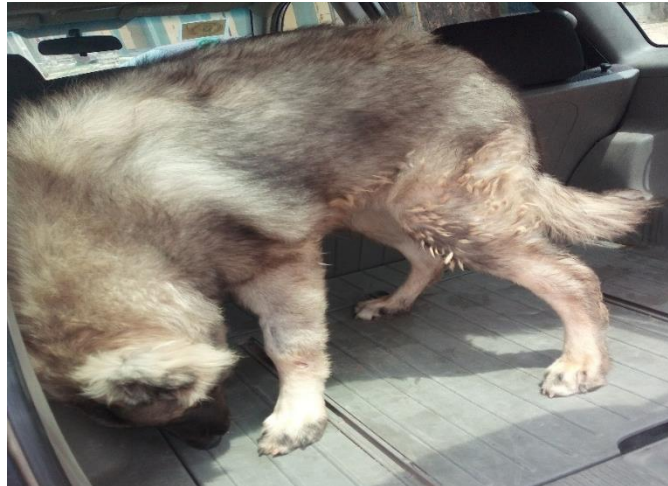## INTRODUCTION

The cause of canine parvoviral enteritis (CPE) is canine parvovirus type 2 (CPV-2) (Miranda *et al.* 2016). A single-stranded DNA virus and non-enveloped with linear genome that belongs to the family Parvoviridae and the genus Protoparvovirus (Chung *et al.* 2020). One of the most frequent causes of sickness and death in dogs between the ages of six weeks and six months is this virus. In-hospital treatment resulted in a 91% survival rate for CPE (Chalifoux *et al.* 2021). New genetic and antigenic variations, CPV-2a, CPV-2b, and CPV-2c, eventually supplanted the original CPV-2, which first appeared in the late 1970s (Parrish *et al.* 1988, Mylonakis *et al.* 2016). After three to seven days of incubation, CPE manifests clinically as fever, lethargy, vomiting, hemorrhagic diarrhea, and appetite loss (Miranda *et al.*, 2016). The virus is spread through the fecal-oral pathway, and in neonatal pups, it has an elective tropism for mitotically active organs such the heart, bone marrow, lymphoid tissues, and gastrointestinal epithelium (Miranda *et al.*, 2016, Eregowda *et al.*, 2020). The germline epithelium of crypts is impacted by intestinal replication; as the germ cells die, the epithelium flattens and the villi shrink, which leads to the development of osmotic diarrhea, which is frequently hemorrhagic. Dehydration brought on by the

intestinal loss of fluids and proteins can lead to hypovolemic shock (Parrish, 1995). Furthermore, as a result of viral replication in bone marrow and lymphoid organs, CPE is linked to a reduction in the number of white blood cells (Miranda *et al.*, 2016). Sepsis, endotoxemia, intestinal bacterial translocation, and secondary bacterial infections are brought on by the breakdown of the intestinal mucosal barrier and immunodepression brought on by viral replication. According to Eregowda *et al.* (2020), hypovolemic and septic shock are typically the causes of death. Due to poor insecurity practices, expensive vaccination costs, and owner ignorance, this disease typically affects dogs that have not received vaccinations. Vaccination is the most effective way to prevent canine parvo virus infection when the pathogen's persistent presence in a given area becomes endemic (Zhao *et al.*, 2016).

## CASE HISTORY

A client presented his 7 months Dog (Bruno) weighing 20kg to Small Animal Clinic of Veterinary Teaching Hospital, University of Maiduguri with the chief complaints of progressive weakness, passing out bloody diarrhea that later became mucoid, with vomiting, and inappetence. History has it that the Dog was vaccinated with one shot of DHLPP vaccine only at five weeks.



**Fig. 1:** Dog (Bruno) on presentation

## CLINICAL EXAMINATION

The dog was presented with an increased temperature of (40.1°C), while, the pulse rate (70 beat per minute), and the respiratory rate

(80 cycle per minute) were within the normal range. The mucous membrane was slightly pale, anorexia, depression, pyrexia, vomiting and profuse foul smelling bloody diarrhea.



**Fig. 2:** Foul smelling bloody diarrhea

#### **DIFFERENTIAL DIAGNOSIS**

- i. Canine distemper
- ii. Haemorrhagic Gastroenteritis
- iii. Helminthosis
- iv. Canine Parvoviral Enteritis

#### **TENTATIVE DIAGNOSIS**


Canine Parvoviral Enteritis?

#### **SAMPLE COLLECTION**

Fecal samples were collect for parvoviral antigen test using rapid test kit (Bionote)<sup>®</sup>

#### **LABORATORY RESULTS**

Fecal parvoviral antigen test result showed positive for canine parvovirus enteritis as indicated in figure 3.



**Fig 3:** The red arrow indicates the Test line (T) which showed positive titre confirming the presence of the viral antibodies. The blue arrow indicates the Control line (C) also known as the Reference line.

#### **TREATMENT AND MANAGEMENT**

Treating dehydration, preventing secondary bacterial infections, controlling vomiting, lowering fever, and promoting recovery are the main goals of the therapeutic approach for treating parvovirus enteritis in dogs. Oxytetracycline is used as a broad-spectrum antibiotic to treat secondary bacterial infections brought on by the compromised gastrointestinal mucosal barrier. Alternatively, amoxicillin could also be used as well. Oxytetracycline is given intramuscularly at a

dose of 7 mg/kg for five days. By blocking dopamine receptors in the chemoreceptor trigger zone, metoclopramide, administered intramuscularly for three days at a dose of 0.4 mg/kg, suppresses vomiting and stops additional electrolyte imbalance and dehydration. Piroxicam, a nonsteroidal anti-inflammatory medication, reduces gastrointestinal discomfort while treating fever and inflammation when given intramuscularly at a dose of 0.3 mg/kg for three days. Injections of vitamin B complex, administered

intramuscularly at a dose of 1 ml/10 kg for three days, help to restore energy and stimulate appetite, both of which are critical for recovery from chronic anorexia.

In order to treat the acute dehydration brought on by vomiting and diarrhea in parvoviral enteritis, fluid treatment is essential. By correcting electrolyte imbalances and providing quick rehydration, lactated Ringer's solution, administered intravenously at a dose of 400 ml for three days, stabilizes the dog's condition. Similarly, lactated Ringer's solution can help maintain circulating blood volume. The significance of a comprehensive and well-coordinated treatment plan is highlighted by

the combination of these therapies, which are designed to address the many consequences of parvoviral enteritis. While intravenous fluid therapy provides immediate relief in acute cases, improving the overall prognosis, most medications are administered intramuscularly to assure efficacy when gastrointestinal absorption is compromised.

#### OUTCOME

The dog finished taking all of its prescriptions, recovered, and was released. On visitation, the dog was noted to have recovered from all the presenting clinical indications of the sickness and it is now eating well (Fig. 4).



**Fig. 4:** Bruno during one of the visitation

#### DISCUSSION

Canine Parvovirus-2 (CPV-2) is the causative agent of canine parvoviral enteritis (CPE), a highly contagious and frequently lethal illness in dogs. The case study demonstrates the common clinical signs and effective treatment of CPE in a 7-month-old dog with unfinished vaccinations. Pyrexia, depression, vomiting, and foul-smelling, bloody diarrhea are the clinical indications of CPE that were seen in this instance, comparable to Dongre *et al.* (2015) reports. These symptoms could be as a result of the impact of the damaged of the gastrointestinal tract, compromising mucosal integrity and causing secondary bacterial translocation. The appearance of pale mucous membranes showed anemia, most likely as a result of early intervention (Santos *et al.*, 2023). This is in line with research by Decaro and Buonavoglia (2012), which highlights that in cases of hemorrhagic enteritis that go untreated, severe anemia may occur later.

When fluid and antibiotics were started as part of the therapeutic procedure, the dogs' condition significantly improved during the first four days, and within six to eight days, the sick canines resumed their usual lives as reported by Dongre *et al.* (2015). The current case report's findings are comparable to those of Singh *et al.* (2008) and Munibullah *et al.* (2017). Viral attraction for rapidly proliferating intestinal crypt cells with the highest mitotic frequency as a result of bacterial flora alteration may be the cause of the highest rate of CPE occurrence in young pups (Deka *et al.*, 2013). By promoting healthy eating, maintaining a clean environment, minimizing crowding, and vaccinating dogs on schedule, canine parvoviral enteritis can be prevented (Odueko, 2019).

#### CONCLUSIONS

As long as the parvovirus disease is identified early and appropriate treatment is initiated,

about 70–80% of dogs can survive. The owner received thorough guidance on the significance of following vaccination schedules, deworming procedures, and keeping the surroundings clean in order to prevent reinfection. To reduce the possibility of parvoviral outbreaks, special attention was paid to separating new puppies and making sure that stringent biosecurity protocols were followed.

#### CONFLICT OF INTEREST

The authors declare no competing interests.

#### REFERENCES

- Chalifoux, N.V., Parker, S.E. & Cosford, K.L. (2021). Prognostic Indicators at Presentation for Canine Parvoviral Enteritis: 322 Cases (2001-2018). *Journal of Veterinary Emergency and Critical Care*, 3: 402-413.
- Chung, H.C., Kim, S.J., Nguyen, V.G., Shin S., Kim, J.Y., Lim, S.K., Park, Y.H., & Park, B.K. (2020). New genotype classification and molecular characterization of canine and feline parvovirus. *Journal Veterinary Sciences*, 21, 43 (9): 2043-2057.
- Decaro, N., Buonavoglia, C. (2012). Canine parvovirus—a review of epidemiological and diagnostic aspects, with emphasis on type 2c. *Veterinary Microbiology*. 155 ( 1): 1–12.
- Deka, D., Phukan, A., & Sarma, D. K. (2013). Epidemiology of parvovirus and coronavirus infections in dogs in Assam. *Indian Veterinary Journal*, 90 (9): 49-51.
- Dongre, J., Mehta, H., Maheshwari, P. (2015). Comparative evaluation of two treatment regimens against canine parvovirus infection. *Haryana Veterinarian*. 54: 83-84.
- Eregowda, C.G., De, U.K., Singh, M., Prasad, H.A., Sarma, K., Roychoudhury P., Rajesh, J.B., Patra, M.K., & Behera, S.K. (2020). Assessment of Certain Biomarkers for Predicting Survival in Response to Treatment in Dogs Naturally Infected with Canine Parvovirus. *Microbial Pathogenesis*, 149, 104485.
- Miranda, C., & Thompson, G. (2016). Canine Parvovirus: The Worldwide Occurrence of Antigenic Variants. *Journal Genetic Virology*
- Munibullah, M., Yousaf, A., Zafar, M. A., Yaqoob, M., Naseer, Z, Nawaz, M. (2017). Canine parvovirus infection in dog: a case report. *Journal of Apply Agricultural Biotechnology* 2(1): 26-28.
- Mylonakis, M., Kalli, I., & Rallis, T. (2016). Canine parvoviral enteritis: an update on the clinical diagnosis, treatment, and prevention. *Veterinary Medicine*, 7, 91-100.
- Oduoko, F.D. (2019). Case report of canine parvoviral enteritis in 12weeks old Rottweiler female puppy. *Journal of Dairy Veterinary Animal Research*. 8(5): 216-223.
- Parrish, C.R. (1995). Pathogenesis of Feline Panleukopenia Virus and Canine Parvovirus. *Baillieres Clinical Haematology*, 1, 57–71.
- Parrish, C.R., Have, P., Foreyt, W.J., Evermann, J.F., Senda, M., & Carmichael, L.E. (1988). The global spread and replacement of canine parvovirus strains, *Journal of Genetic Virology*, 69, 1111-1116
- Santos, T. G., Orlandin, J. R., Almeida, M. F., Scassiotti, R. F., Oliveira, V. C., Santos, S. I. P., Pereira, V. M., Pinto, P. A. F., Mariano Junior, C. G., & Ambrósio, C. E. (2023). Ozone therapy: protocol for treating canine parvovirus infection. *Brazilian Journal of Veterinary Medicine*, 45, e004622. <https://doi.org/10.29374/2527-2179.bjvm004622>
- Singh, G.D., Jadon, N.S., & Sharma, V.K. (2008). Effect of fluid therapy in acute abdominal abnormalities in canine patients. *Indian Veterinary Journal*, 28 (2): 139-140.
- Zhao, Z., Liu, H., Ding, K., Peng C, Xue, Q., & Yu, Z. (2016). Occurrence of canine parvovirus in dogs from Henan province of China in 2009–2014. *BMC Veterinary Research*, 12 (1):138