



## Research Article

# Phytochemical screening and gastroprotective effect of aqueous leaf extract of *Saccharum spontaneum* in Aspirin-induced mucosal ulceration in rats

Usman B.,<sup>1,2\*</sup>, Wulgo, A. M.<sup>3</sup>, Timta, M. H.<sup>2</sup>, Waziri, A.<sup>4</sup>, Maina, U. A.<sup>5</sup>, Abdulsalam, H.<sup>4</sup>, Jibril, I.<sup>6</sup>, Idowu, A.<sup>1</sup>

<sup>1</sup>Department of Biochemistry, Ahmadu Bello University, Zaria, Nigeria.

<sup>2</sup>Department of Veterinary Physiology and Biochemistry, University of Maiduguri, Nigeria

<sup>3</sup>Department of Veterinary Anatomy, University of Maiduguri, Nigeria.

<sup>4</sup>Department of Veterinary Pathology, University of Maiduguri, Nigeria.

<sup>5</sup>Department of Veterinary Pharmacology and Toxicology, University of Maiduguri, Nigeria.

<sup>6</sup>Department of Science Laboratory Technology, Federal Polytechnic Bauchi, Nigeria

\*Corresponding author's Email: [abbalaushi@unimaid.edu.ng](mailto:abbalaushi@unimaid.edu.ng), [doi.org/10.55639/607.02010022](https://doi.org/10.55639/607.02010022)

## ARTICLE INFO: ABSTRACT

### Keywords:

*Saccharum spontaneum*,  
Gastric ulcer,  
Histopathology,  
Photochemistry,  
Aspirin

*Saccharum spontaneum* is a medicinal herb used to treat gastritis, diuresis, and anaemia, but its preventive action against stomach mucosal injury remains unknown. The study investigates the phytochemical screening and gastroprotective effect of aqueous leaf extract of *Saccharum spontaneum* in aspirin-induced mucosal ulceration in rats. Thirty-five adult rats were randomly divided into five groups (n=7 per group). Group A (control group); Group B was given 200 mg/kg of aspirin; Group C was administered 10 mg/kg of omeprazole; Group D and E received 200 and 400 mg/kg of AESS, respectively. Prophylactic treatment was carried out orally for 14 consecutive days before aspirin administration. The rats were anaesthetized with chloroform and sacrificed by cervical dislocation at the end of the study. Stomachs were harvested for ulcer index and histopathological assessment. The extract showed significant phytoconstituents, including alkaloids (5.01%), flavonoids (10.13%), phenols (13.89%), saponins (5.78%), and tannins (12.07%). Aspirin significantly ( $P \leq 0.05$ ) increased the mean ulcer index ( $5.75 \pm 0.50$ ). Pretreatment with AESS (200 mg/kg and 400 mg/kg) significantly reduced the mean ulcer index ( $2.75 \pm 0.50$  and  $2.00 \pm 0.96$ , respectively) compared to the aspirin-ulcerated group ( $5.75 \pm 0.50$ ). Extensive mucosal erosions, loss of lining epithelium, haemorrhages, inflammatory infiltration, and deep ulceration were observed in the gastric tissue of aspirin-treated rats. Administration of AESS-protected aspirin-induced gastric mucosal injury with no ulcer craters, haemorrhage, or mild abrasion on the lining epithelium. In conclusion, *Saccharum spontaneum* can partly protect the gastric mucosa against aspirin-induced damage to a degree similar to the classical omeprazole.

Corresponding author: Usman B., Email: [abbalaushi@unimaid.edu.ng](mailto:abbalaushi@unimaid.edu.ng)

Department of Veterinary Physiology and Biochemistry, University of Maiduguri, Nigeria

## INTRODUCTION

The gastric mucosa is highly vulnerable to injury due to the stomach's particular position and functional characteristics. This damage can cause stomach mucosal erosion, bleeding, and even ulcers, which are intimately related to the development of gastric cancer (Mera *et al.*, 2018; Lee *et al.*, 2016). The pathophysiology of gastric injury associated with NSAID administration depends partly on cyclooxygenase inhibition and partly on cyclooxygenase-independent mechanisms, which result mainly from local direct actions (Scarpignato & Hunt, 2010). Cyclooxygenase blockade increases the susceptibility of gastric mucosa to NSAID-induced lesions by suppressing several prostaglandin-mediated protective functions. For instance, prostaglandins reduce the activation of neutrophils and the local release of reactive oxygen species (ROS) (Fornai *et al.*, 2011). Remarkably, multifactorial determinants are implicated in the development of gastric ulcers, such as smoking, alcohol, *Helicobacter* infection, psychological stress, and excessive use of nonsteroidal anti-inflammatory drugs (NSAIDs) (Awaad *et al.*, 2013). The imbalance between these harmful factors in the gastric lumen and protective mechanisms in the gastroduodenal mucosa led to severe gastric irritation and gastrointestinal (GI) symptoms ranging from uncomplicated dyspepsia to potentially fatal GI bleeding and perforations (Almuzafar, 2018). Aspirin use has been linked to potentially serious dose-dependent gastrointestinal complications such as gastrointestinal ulceration and localized mucosal tissue infiltration, blood vessel congestion, as well as bleeding in the stomach, duodenum, and colon (Goldstein & Cryer, 2015; Lucchi *et al.*, 2012). Consequently, these medicines have been used to produce experimental ulcers in rats, and physicians and biomedical scientists are looking for prophylactic drugs to combat this dangerous side effect of such a valuable drug (Rafaniello *et al.*, 2016).

Gastric ulcers affect about 25–30% of the world's population, with a mortality rate of approximately one death per 10,000 cases (Carneiro *et al.*, 2018; Zhang *et al.*, 2011). In Nigeria, it is estimated to cause 5090 deaths annually (Kuna, 2019). The primary therapeutic remedy for this condition is antisecretory medicine, such as irreversible

proton pump inhibitors (Bi *et al.*, 2017; Goldstein & Cryer, 2015). However, successful long-term use of these medications might create major consequences and worsen the illness (Kangwan *et al.*, 2014), which highlights the need for safer and more effective antiulcer agents. In experimental models of stomach ulcers, a wide range of chemical compounds, herbs, and plant extracts are therapeutic. These substances or extracts have antisecretory, cytoprotective, anti-inflammatory, and antioxidant activities that contribute to their gastroprotective effects (Li *et al.*, 2013; Antonisamy *et al.*, 2015; Balogun *et al.*, 2015).

*Saccharum spontaneum* Linn is regarded as a promising medicinal plant in traditional systems of medicine and is used to cure ulcers in northern Nigeria. Thus, developing an antiulcerogenic medicine from plant origins while maintaining efficacy and safety will assist millions of suffering individuals (Oluranti *et al.*, 2012; Celestina *et al.*, 2018).

## MATERIALS AND METHODS

### Identification of Plant

The leaves of *Saccharum spontaneum* were obtained from Samaru, Sabongari local government area, Kaduna State, Nigeria. The plant was authenticated at the herbarium unit of the Department of Botany, Ahmadu Bello University, Zaria, Nigeria (Voucher number: 900111). The leaves were washed, air-dried, pounded into a fine powder with a wooden mortar and pestle and stored in sealed plastic containers until needed.

### Preparation of Plant Extract

A successive extraction of the dried powdered leaves of *Saccharum spontaneum* was carried out for 2-3 days (Farnsworth, 1988). Precisely 600 grams of the powdered leaves were soaked in 2.5 litres of distilled water in an extractor for 48 hours at room temperature while stirring frequently and sieved using a muslin cloth to obtain the aqueous extracts. To prevent solvent evaporation at ambient pressure, the extractor is sealed. The resulting extract was filtered with Whatman number 1 filter paper. The extract was concentrated in a water bath at 40–45°C. The *Saccharum* extract was transferred into a glass beaker, which was subsequently sealed with foil paper and placed in a fridge for storage at 4°C for future use.

### Experimental Animals

Thirty-five (35) adult male albino rats weighing between 200 and 250 g were collected from the animal house, Department of Biochemistry, Faculty of Life Sciences, Kaduna State University. To avoid coprophagy, the animals were confined in cages with high flooring made of broad wire mesh. The habitat was clean and conducive for the animals. Standard pelleted feed and water were provided in abundance. They were exposed to the laboratory setting for two weeks to acclimate before the experiment began.

#### **Animal Groupings**

Thirty-five (35) adult male rats were divided randomly into five groups, each comprising seven (7) rats. Ulcers were induced from group B-E by oral aspirin administration (200 mg/kg). Rats were treated with the extracts and standard drug following the dose and mode of administration of Berenguer *et al.* (2006) for two weeks and fasted 48 hours before ulcer induction. The specific doses (200 mg/kg and 400 mg/kg) of *Saccharum spontaneum* extract used in this study reflect 4% and 8% of the highest dose (5000 mg/kg) from preliminary acute toxicity experiments of the plant extract. The different groups were assigned as described below:

Group A (Normal control): Administered a vehicle (water) P.O.

Group B (Positive control): Administered aspirin (200 mg/kg) P.O.

Group C: Administered Omeprazole (10 mg/kg) and aspirin (200 mg/kg) P.O.

Group D: Administered AESS (200 mg/kg) and aspirin (200 mg/kg) P.O.

Group E: Administered AESS (400mg/kg) and aspirin (200 mg/kg) P.O.

#### **Induction of Gastric Ulcer**

Aspirin, a nonsteroidal anti-inflammatory medicine (NSAID), was utilized as an ulcerogenic agent at 200 mg/kg body weight (Rao & Vijayakumar, 2007). After four hours of administering aspirin, the rats were anaesthetized with chloroform and sacrificed by cervical dislocation using a clean razor blade. The abdomen of the rats was exteriorized to harvest the stomach. The stomach of each rat was cut open along the greater curvature, and the gastric portion was removed and washed in a physiological saline solution. Ulcers were assessed in the glandular portion of the stomach using the modified method of Magistretti *et al.* (1988).

#### **Phytochemical Screening**

According to the methods described by Santhi *et al.* (2015) and Longbap *et al.* (2018), a qualitative phytochemical analysis was performed on the aqueous extract to screen for alkaloids, flavonoids, tannins, glycosides, triterpenoids, anthraquinones, saponins, phenols, and steroids, while quantitative estimation of the phytoconstituents was carried out according to the methods described by Krishnaiah *et al.* (2009) and Sathya *et al.* (2013) to estimate alkaloids, flavonoids, saponins, tannins and total phenolics, respectively.

#### **Estimation of Ulcer Index**

According to the method described by Magistretti *et al.* (1988), gastric lesions in the glandular region of the stomach were located, and an arbitrary scoring system of 0–6 points was used to grade the incidence and severity of the lesions. 0 = no lesions, 1 = 1–3 small lesions, 2 = 1–3 large lesions, 3 = 1–3 thick lesions, 4 = more than 3 small lesions, 5 = more than 3 large lesions, and 6 = more than 3 thick lesions. The mean ulcer index (UI) was calculated by adding the total severity values in each group of rats and dividing by the number of animals.

#### **Preparation of Tissue for Histopathological Studies**

About 1cm of gastric tissue was collected from each group and immediately fixed in a 10% buffered formalin solution for 48 hours. The fixed tissues were routinely processed and dehydrated at graded alcohol levels (70%, 95%, and 100%) using an automatic tissue processor. The tissue samples were cleared using xylene-embedded tissues, and a microtome knife was affixed to a microtome apparatus. Subsequently, the sliced tissue sections were carefully placed onto a grease-free, pristine surface for further analysis. The glass slide was exposed to the surrounding environmental conditions to facilitate the drying process, and a staining procedure was performed with hematoxylin and eosin stain (H and E). The histological slides were examined on a microscope x100 magnification (Luna, 1960).

#### **Statistical Analysis**

The data obtained were presented as mean  $\pm$  SD. A one-way analysis of variance (ANOVA) was employed to determine significant differences between groups using SPSS version 20 software (Statistical Package

for Social Sciences, Inc., Chicago, IL, USA), followed by the Duncan Multiple Range Test (DMRT) for multiple comparisons. Significant differences were defined as P-values less than or equal to 0.05 ( $P \leq 0.05$ ).

#### Ethical Statement

Ethical clearance was obtained from the Ahmadu Bello University Committee on Animal Use and Care with approval number ABUCAUC/2016/124, Zaria, Nigeria. The ethical guidelines of the Council for International Organizations of Medical Sciences (2015) and the International Council for Laboratory Animal Science (2012) were strictly followed.

## RESULTS

### Phytochemical Screening of *S. spontaneum* Extract

The preliminary qualitative phytochemical screening of *S. spontaneum* aqueous leaf extract indicated the presence of alkaloids, carbohydrates, flavonoids, glycosides, phenols, saponins, steroids, tannins, and triterpenoids, but no anthraquinone, as shown in Table 1.

### Quantitative Phytochemical Analysis of *S. spontaneum* Extract

Quantitative estimations of the phytoconstituents of aqueous extract of *S. spontaneum* showed considerable alkaloids, flavonoids, saponins, tannins and phenols (table 2).

**Table 1:** Preliminary phytochemical contents of *S. spontaneum* extract

Phytochemical Constituent	Test	Result
Alkaloids	Dragendorff's	+
Anthraquinones	Borntrager's	-
Carbohydrates	Molisch's	+
Cardiac glycosides	L-Buchard's	+
Flavonoids	NaOH	+
Phenols	Evan's	+
Saponins	Frothing's	+
Steroids	Evan's	+
Tannins	Ferric chloride	+
Triterpenoids	Evan's	+

Key + =Present; - = Absent

**Table 2:** Phytochemical estimations *S. spontaneum* extract

Phytochemical Constituent	Amount (%)
Alkaloids	5.01
Flavonoids	10.13
Phenols	13.89
Saponins	5.78
Tannins	12.07



**Table 3:** Effect of *S. spontaneum* extract on aspirin induced gastric lesions

Groups	Treatment	Dose (mg/kg)	Mean Ulcer Index (MUI)
A	Control	10	0.00
B	Aspirin	200	5.75 ± 0.50 <sup>a</sup>
C	Omeprazole	10	1.5 ± 0.58 <sup>b</sup>
D	AESS	200	2.75 ± 0.50 <sup>b</sup>
E	AESS	400	2.00 ± 0.96 <sup>b</sup>

Values are mean ± SD of 7 rats per group. Different superscript in the same column are Significant at (P<0.05) using one way analysis of variance (ANOVA) followed by Duncan Multiple Range Test (DMRT). AESS = Aqueous extract of *S. spontaneum*.

NB: Animals were treated with extracts for 14 days before administration of Aspirin.

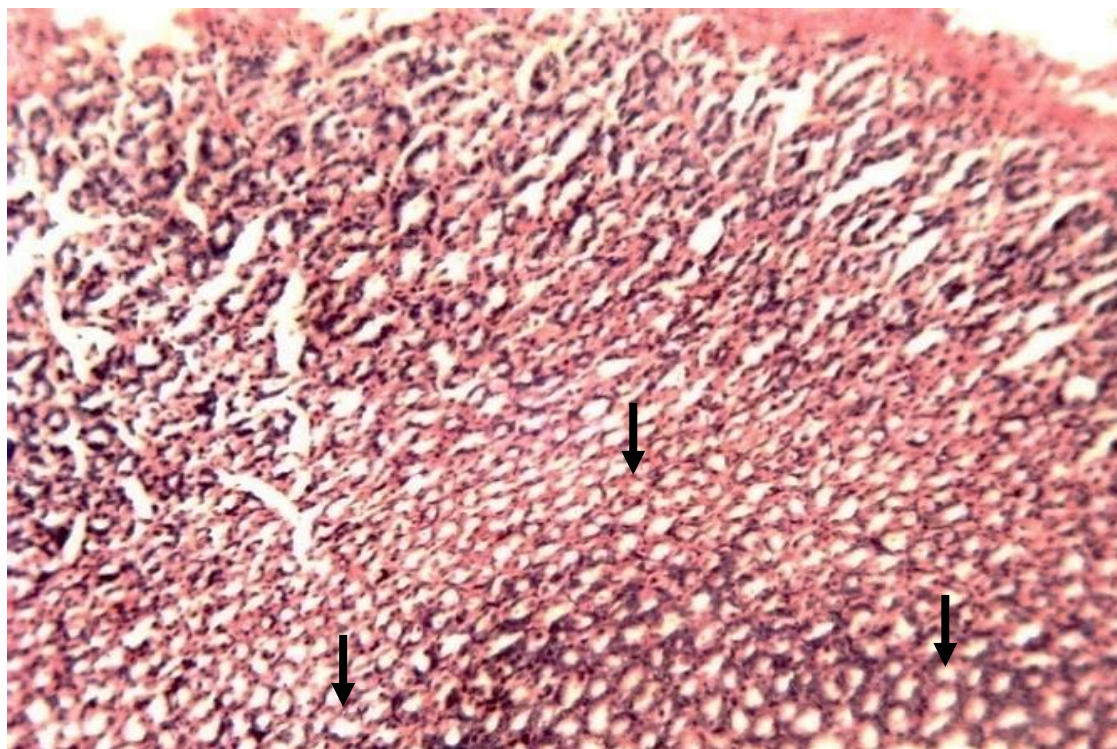
a = No statistical significance with Aspirin treated group at p<0.05.

b = Significantly different from Aspirin treated group but no statistical significance with omeprazole and extract treated group at p<0.05.

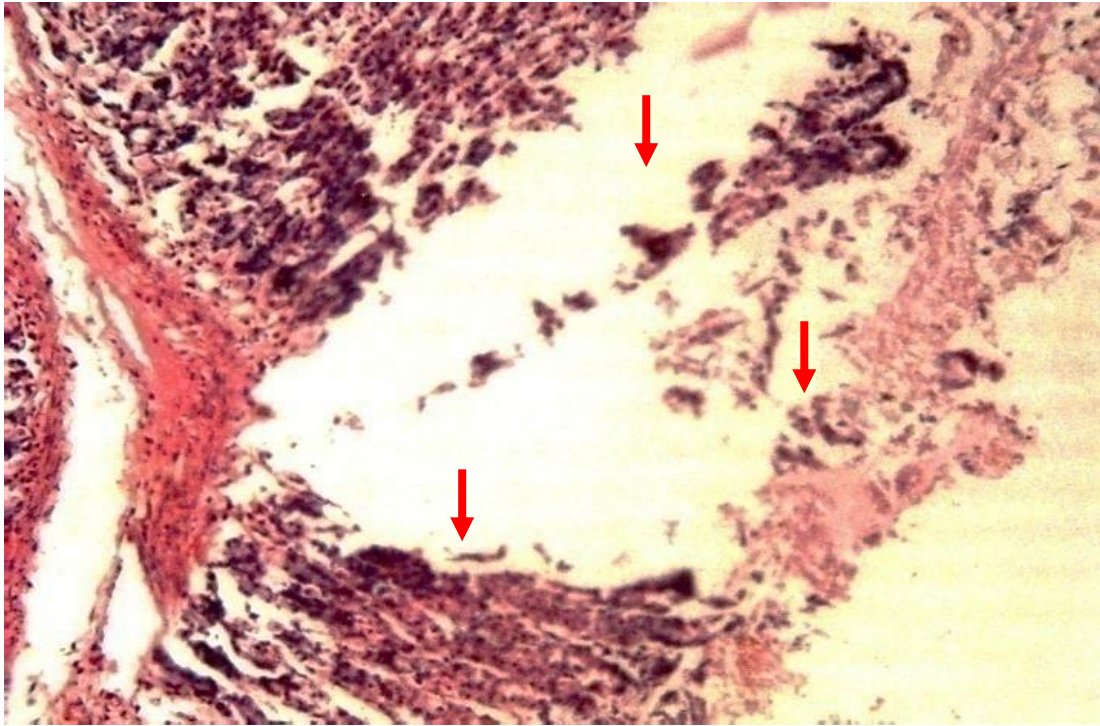
### Histopathological Examinations

The gastroprotective efficacy of *S. spontaneum* was assessed by microscopic analysis of the rat's stomach mucosa. Plate 1 shows a standard histological characteristic of the stomach mucosa. Oral aspirin treatment (200 mg/kg) caused significant mucosal necrosis, blood vessel congestion, haemorrhages, loss of lining epithelium, numerous ulcers, and an inflammatory response marked by neutrophil infiltration (Plate 2). Omeprazole (10 mg/kg) improved stomach mucosal protection, with

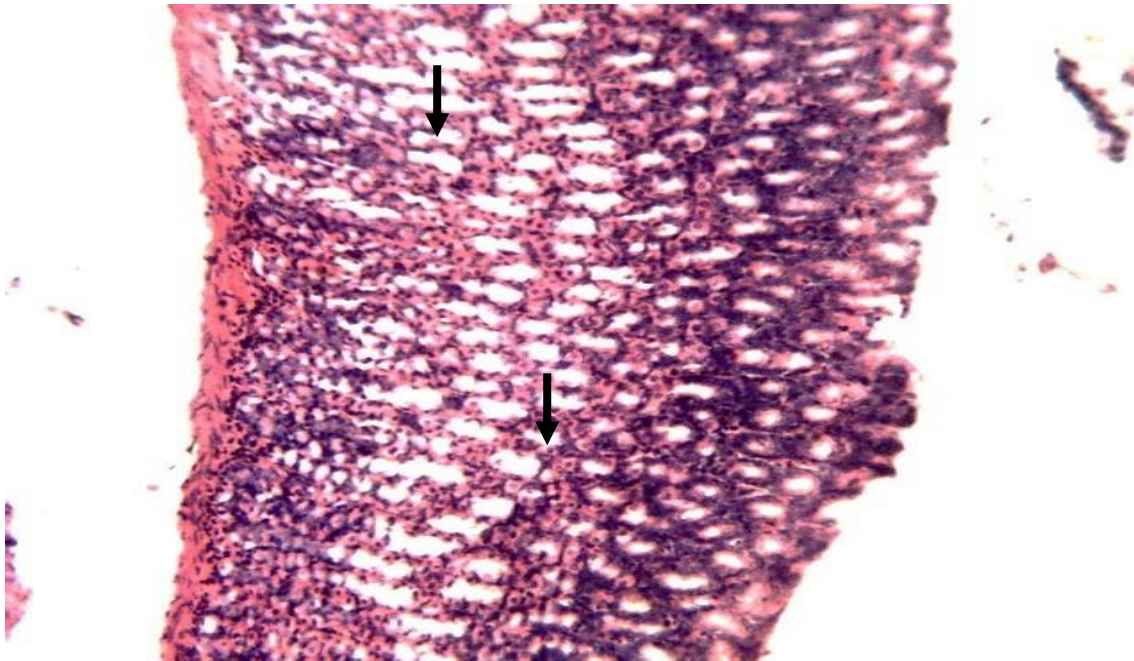modest blood vessel congestion, mild tissue infiltrations, and no bleeding (Plate 3). Similarly, rats treated with 200 mg/kg and 400 mg/kg of the aqueous extract showed modest superficial excoriation on the lining epithelium, minimal apical necrosis, and no bleeding (Plates 4 and 5). Changes in the gastric wall and discontinuity of the epithelial lining in the glandular region with no ulcer craters were observed in a dose-dependent manner in rats administered with the extracts.



**Plate 1:** Photomicrograph showing normal features of gastric mucosa of Wister rats (Black arrow). H & E x100.

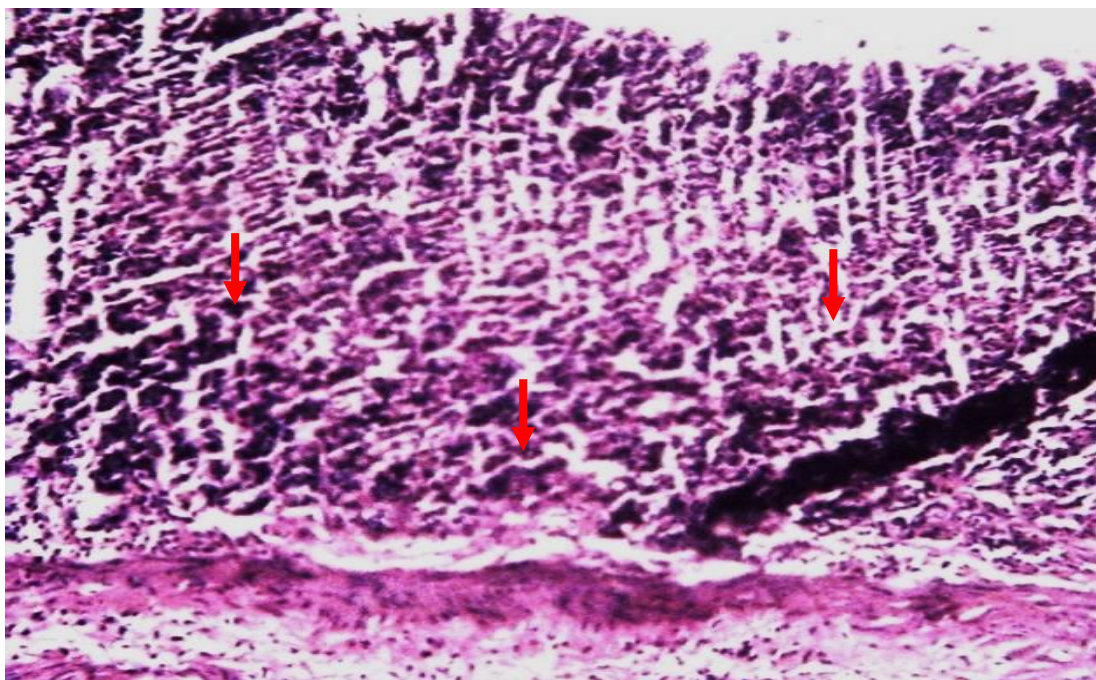


**Plate 2:** Photomicrograph of gastric mucosa of Wister rats showing intense mucosal necrosis, loss of lining epithelium, hemorrhages, infiltration and deep ulceration (Red arrow). H & E x100

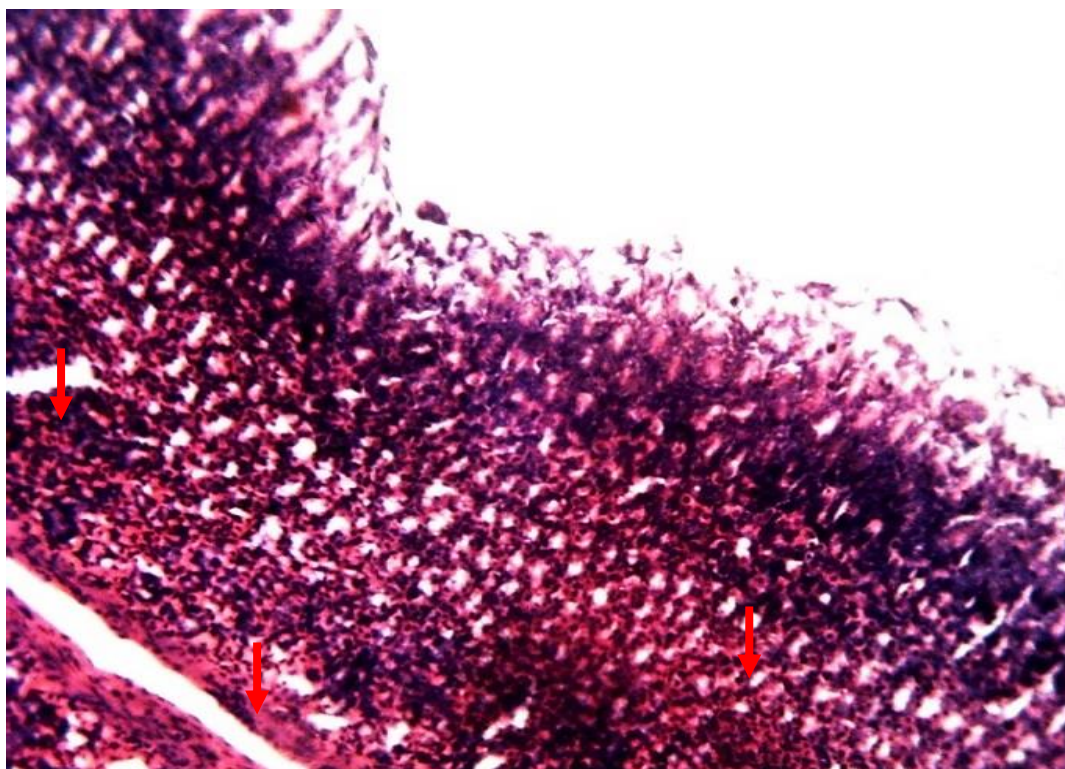


**Plate 3:** Photomicrograph of gastric mucosa of Wister rats showing mild superficial excoriation on lining epithelium with no ulceration (Black arrow). H & E x100.





**Plate 4:** Photomicrograph of gastric mucosa of Wister rats showing moderate superficial abrasion of submucosal layer with no ulcer (Red arrow). H & E x100



**Plate 5:** Photomicrograph of gastric mucosa of Wister rats exhibiting slight mucosal epithelial change with no ulcer (Red arrow). H & E x100.

## DISCUSSION

Gastric ulcer is one of the most upsetting health disorders, seeking alternate therapy after the failure of most antiulcer drugs. Several factors contribute to gastric ulcers, the most common being nonsteroidal anti-inflammatory medications, *H. pylori*, environmental factors, alcohol consumption, and lifestyle factors (Pradhan *et al.*, 2013). The standard medications were ranitidine, omeprazole, and sucralfate from different classes, and their significant findings are consistent with the research of other investigators (Urumarudappa *et al.*, 2023; Balmik *et al.*, 2019; Zangeneh *et al.*, 2019).

Globally, herbal medications are currently in great demand for primary healthcare due to their low cost, greater cultural acceptability, improved bodily compatibility, and low side effects.

Our study reported that the pretreatment with *S. spontaneum* L. leaves displayed a significant gastroprotective effect in aspirin-induced gastric ulcers. Bioactive components in medicinal plants, such as tannins, alkaloids, phenols, and flavonoids, enhance their effectiveness in treating ulcer diseases. These constituents are frequently chosen for their lack of unpleasant side effects (Jhansi *et al.*, 2017). Additionally, they prevent gastric lesions and protect the mucosa from necrotic agents (Alanko *et al.*, 1999).

Flavonoids have shown gastroprotective and antiulcer effects, according to studies by Zhang *et al.* (2020) and Maury *et al.* (2012). These effects are crucial for resisting aggressive factors (gastric acid, pepsin, and oxidative stress) and bolstering protective factors (mucus, bicarbonate, prostaglandins, and antioxidant enzymes). Therefore, the gastroprotective potential of *S. spontaneum* has been substantiated by the presence of flavonoids in its leaves. Tannins promote the creation of gastric mucosa and reduce acid output while inhibiting pepsinogen production, decreasing ulcerogenic lesions, burns, and inflammation (La Casa *et al.*, 2000). According to our findings, the plant has a high tannin content, which may be related to its ability to lessen the adverse effects of aspirin. Tannin also interferes with the gastric proton pump (H<sup>+</sup>/K<sup>+</sup> - ATPase) in the final step of gastric acid secretion located in the gastric membrane vesicles, which catalyzes the

electro-neutral exchange of intracellular hydrogen and extracellular potassium (Shin *et al.*, 2006).

According to a recent study by Mota *et al.* (2009), the combination of flavonoids and tannins can treat stomach ulcers through several mechanisms, including their ability to scavenge free radicals and their antioxidant properties; they can also protect the gastric mucosa from substances that cause ulcers, increase the production of mucus and their antisecretory activity, and stop the growth of *Helicobacter pylori*. Additionally, after pretreatment with phenolic compounds in indomethacin-induced gastric mucosal damage, histological changes, free and total acidity levels, ulcer index, and gastric juice volume were found to decrease (Katary & Salahuddin, 2017). Based on these findings, the high phenol content of *S. spontaneum* supports its gastroprotective effect. Consequently, the abundance of these phytochemicals in the leaves of *S. spontaneum* suggests their therapeutic effects for humans. This is because the benefits of plants for human health depend on the availability of active ingredients (Aguoru *et al.*, 2016; Nduche *et al.*, 2015).

Furthermore, the histological results concurred with Alazzouni *et al.* (2021) and confirmed the earlier findings. The stomach mucosa was severely damaged by aspirin, exhibiting hemorrhagic injury, mucosal degradation, loss of epithelial cells, necrosis, and infiltration of inflammatory cells. On the surfaces of endothelial cells, aspirin may stimulate the expression of cell adhesion molecules, damage the stomach mucosa and recruit leukocytes to inflammatory and hemorrhagic areas. Leukocyte adhesion has been demonstrated to impair microcirculation, causing ischemia and mucosal injury that form ulcers (Eamlamnam *et al.*, 2006). Due to the acidic environment, a small dose of aspirin causes GI mucosal and systemic effects via inhibiting COX-1. In the absence of natural prostaglandins that encourage the creation of bicarbonate and mucus, aspirin remains non-ionized, causing it to accumulate in stomach mucosal cells, changing their permeability, and leading to ulceration within minutes of administration (Cryer & Mahafey, 2014). *S. spontaneum* exhibited an intact histological structure of the mucosa and reduced inflammation, especially



at high doses, by reducing the ulcerative lesion index and histological damage and enhancing vascular permeability in the stomach. Inflammation is an intricate immune system response to tissue damage defined by increased proinflammatory cytokines from immune cells (Wu *et al.*, 2018). The ameliorative effect of *S. spontaneum* on gastric mucosal damage is evidence of its therapeutic potential, and the mechanism might be attributed to the cytoprotective properties of the extract's phytoconstituents. These results offer empirical support for a traditional application of the *S. spontaneum*. Nonetheless, further research is necessary to clarify the exact mechanism(s) of action and identify the bioactive components accountable for the extract's gastroprotective properties.

### CONCLUSION

The current study assessed the potential gastroprotective effect of *Saccharum spontaneum* leaves against aspirin-induced gastric ulcers in rats. Data presented a significant protective effect of the plant against gastric ulcers as it reduced gastric mucosal injury with potential cytoprotective properties in its active principles. Therefore, it may be considered a promising therapeutic agent for preventing or treating gastric ulceration.

### ACKNOWLEDGEMENT

We acknowledge the kind assistance provided by the technicians and other staff of the Department of Pharmacology, Ahmadu Bello University, Zaria, Nigeria.

### CONFLICT OF INTEREST

There is no conflict of interest in the current study.

### REFERENCES

- Aguoru, C. U., Pilla, C., and Olasan, J. O. (2016). Phytochemical screening of *Xylopiya aethiopicum* with emphasis on its medicinally active principles. *Journal of Medicinal Plants Research*, 10(22), 306-309.
- Ahmad, B. A., Rao, M. U., Muhammad, A., Zin, T., Mohamad, N. H., Mohamad, N., and Mohd, K. S. (2014). Reviews of herbal and their secondary metabolites in the treatment of ulcerative colitis and peptic ulcer. *Journal of Applied Pharmaceutical Science*, 4(8), 080-090.
- Akbar, S., Ishtiaq, S., Ajaib, M., and Hanif, U. (2021). Preliminary Phytochemical Analysis, Anthelmintic, Insecticidal and Protective Effect of *Dicliptera bupleuroides* Nees in Ethanol-induced Gastric Mucosal Damage Rats: Phytochemical and biological activities of *Dicliptera bupleuroides* Nees. *Proceedings of the Pakistan Academy of Sciences: B. Life and Environmental Sciences*, 58(1), 53-63.
- Alanko, J., Riutta, A., Holm, P., Mucha, I., Vapaatalo, H., and Metsä-Ketelä, T. (1999). Modulation of arachidonic acid metabolism by phenols: relation to their structure and antioxidant/prooxidant properties. *Free Radical Biology and Medicine*, 26(1-2), 193-201.
- Alazzouni, A.S., Daim, M.A., Gabri, M.S., Fathalla, A.S, Albrakati, A., AlHazani, T., and Hassan, B.N. (2021). Protective effect of pomegranate peels extracts against stomach peptic-ulcer induced by brexin in albino rats. Research Square. <https://doi.org/10.21203/rs.3.rs-474368/v1> (Preprint Version 1).
- Almuzafar, H.M. (2018). Effect of *Moringa oleifera* leaves extract on the oxidative stress and gastric mucosal ulcer induced by indomethacin in rats. *Afr J Biotech* 17(3):51–56.
- Antonisamy, P., Duraipandiyan, V., Aravinthan, A., Al-Dhabi, N. A., Ignacimuthu, S., Choi, K. C., and Kim, J. H. (2015). Protective effects of friedelin isolated from *Azima tetraantha* Lam. against ethanol-induced gastric ulcer in rats and possible underlying mechanisms. *European Journal of Pharmacology*, 750, 167-175.
- Awaad, A.S., El-Meligy, R.M., and Soliman, G.A. (2013). Natural products in treatment of ulcerative colitis and peptic ulcer. *J. Saudi Chem. Soc.* 17(1):101–124.
- Balmik, M., Dubey, G., Ghauary, S. K., and Jain, P. K. (2019). Phytochemical Screening and Evaluation of Antiulcer Activity of Hydroalcoholic Extract of *Lilium Candidum* Flowers. *Journal of Drug Delivery and Therapeutics*, 9(4-A), 646-650.
- Balogun, S. O., Damazo, A. S., and de Oliveira Martins, D. T. (2015). Ggastroprotective and possible

- mechanism of actions of *Helicteres sacarolha* in experimental animals. *Journal of ethnopharmacology*, 166, 176-184.
- Berenguer, P. L., Sanchez, L. M., Quillea, A., Lopez-Barreiro, M., De Haro, O., Galvez, J. and Martin, M. J. (2006). Protective and antioxidant effects of *Rhizophora mangle* L. against NSAID-induced gastric ulcer. *Journal of Ethnopharmacology*: 77: 1-3.
- Bi, W., Hu, L., and Man, M. Q. (2017). Anti-ulcerogenic efficacy and mechanisms of edible and natural ingredients in NSAIDs-induced animal models. *African Journal of Traditional, Complementary and Alternative Medicines*, 14(4), 221-238.
- Carneiro, J. G., Holanda, T. D. B. L., Quinderé, A. L. G., Frota, A. F., Soares, V. V. M., Sousa, R. S. D., and Benevides, N. M. B. (2018). Gastroprotective effects of sulphated polysaccharides from the alga *Caulerpa mexicana* reducing ethanol-induced gastric damage. *Pharmaceuticals*, 11(1), 6.
- Celestina, O. I., Sunday, A. A., Duncan, O. A., and Herbert, C. A. (2018). In vivo antiplasmodial activities of four Nigerian plants used singly and in polyherbal combination against *Plasmodium berghei* infection.
- Cryer, B., and Mahafey, K.W. (2014). Gastrointestinal ulcers, the role of aspirin, and clinical outcomes: pathobiology, diagnosis, and treatment. *J. Multidiscip Healthc.* 7:137–146. <https://doi.org/10.2147/JMDH.S54324>.
- Eamlamnam, K., Patumraj, S., Visedopas, N., and Thong-Ngam, D. (2006). Effects of Aloe vera and sucralfate on gastric microcirculatory changes, cytokine levels and gastric ulcer healing in rats. *World Journal of Gastroenterology*. 12(13):2034–2039. <https://doi.org/10.3748/wjg.v12.i13.2034>.
- Farnsworth, N. R. (1988). Screening plants for new medicines. Wilson Education Press. Washington, D.C. *National Academy*. pp. 8397.
- Fornai, M., Natale, G., Colucci, R., Tuccori, M., Carazzina, G., Antonioli, L., and Del Tacca, M. (2011). Mechanisms of protection by pantoprazole against NSAID-induced gastric mucosal damage. *Naunyn-Schmiedeberg's archives of pharmacology*, 372(1), 79-87.
- Goldstein, J. L., and Cryer, B. (2015). Gastrointestinal injury associated with NSAID use: a case study and review of risk factors and preventative strategies. *Drug, healthcare and patient safety*, 31-41.
- Jhansi, K., Jayarambabu, N., Reddy, K. P., Reddy, N. M., Suvarna, R. P., Rao, K. V., and Rajendar, V. (2017). Biosynthesis of MgO nanoparticles using mushroom extract: effect on peanut (*Arachis hypogaea* L.) seed germination. *3 Biotech*, 7, 1-11.
- Kangwan, N., Park, J. M., and Hahm, K. B. (2014). Development of GI-safe NSAID; progression from the bark of willow tree to modern pharmacology. *Current Opinion in Pharmacology*, 19, 17-23.
- Katary, M.A., and Salahuddin, A. (2017). Gastroprotective effect of vanillin on indomethacin-induced gastric ulcer in rats: protective pathways and antisecretory mechanism. *Clin. Exp. Pharmacol.* 7:232.
- Krishnaiah, D., Devi, T., Bono, A., and Sarbatly, R. (2009). Studies on phytochemical constituents of six Malaysian medicinal plants. *Journal of medicinal plants research*, 3(2), 67-72.
- Kuna, L., Jakab, J., Smolic, R., Raguz-Lucic, N., Vcev, A., and Smolic, M. (2019). Peptic Ulcer Disease: A Brief Review of Conventional Therapy and Herbal Treatment Options. *Journal of clinical medicine*, 8(2), 179. <https://doi.org/10.3390/jcm8020179>
- La Casa, C., Villegas, I., De La Lastra, C. A., Motilva, V., and Calero, M. M. (2000). Evidence for protective and antioxidant properties of rutin, a natural flavone, against ethanol induced gastric lesions. *Journal of ethnopharmacology*, 71(1-2), 45-53.
- Lange, H.F. (1957). Salicylates and Gastric Hemorrhage: I. Occult Bleeding. *Gastroenterology*, 33(5), 770-777.

- Lee, Y. C, Chiang, T. H, Chou, C. K, Tu, Y. K, Liao, W. C, Wu, M. S, and Graham, D. Y. (2016). Association between *Helicobacter pylori* eradication and gastric cancer incidence: a systematic review and meta-analysis. *Gastroenterology*; **150**:1113–1124 e1115.
- Levrat, M., and Lambert, R. (1960). Aspirin, gastrointestinal bleeding, and peptic ulcer. *The American Journal of Digestive Diseases*, *5*, 623-631.
- Li, W., Huang, H., Niu, X., Fan, T., Mu, Q., and Li, H. (2013). Protective effect of tetrahydrocoptisine against ethanol-induced gastric ulcer in mice. *Toxicology and applied pharmacology*, *272*(1), 21-29.
- Longbap, B. D., Ushie, O. A., Ogah, E., Kendenson, A. C., and Nyikyaa, J. T. (2018). Phytochemical screening and quantitative determination of phytochemicals in leaf extracts of *Hannoa undulata*. *International Journal of Medicinal Plants and Natural Products*, *4*(2), 32-38.
- Lucchi, S., Valkhoff, V., Kollhorst, B., Schink, T., Garbe, E., Arfe, A., and Villa, M. (2012). Risk of upper gastrointestinal complications associated with use of individual non-steroidal anti-inflammatory drugs in the SOS Project. *Pharmacoepidemiology and Drug Safety*, *21*(Suppl. 3), 409-410.
- Luna, G. H. (1960). Manual of the Histological Staining Method of Armed Forces Institute of Pathology, 5<sup>th</sup> Edition, McGraw-Hill Book Company, N.Y., pp. 46.
- Magistretti, M. J., Conti, M. and Cristoni, A. (1988). Anti-ulcer activity of an anthocyanidin from *Vaccinium myrfillus*, *Arzneimittle forschung, Journal of Drug Research*.**38**:686-690.
- Maury, P.K., Jain, S.K., and Shashi, A. (2012) A review on antiulcer activity. *Int J. Pharma. Sci. Res.* *3*:2487–2493.
- Mera, R. M, Bravo, L. E, Camargo, M. C, Bravo, J. C, Delgado, A. G, Romero-Gallo, J, Yopez, M. C, Realpe, J. L, Schneider, B. G, Morgan, D. R, Peek, R. M Jr, Correa, P, Wilson, K. T, and Piauelo, M. B. (2018). Dynamics of *Helicobacter pylori* infection as a determinant of progression of gastric precancerous lesions: 16-year follow-up of an eradication trial. *Gut*; **67**:1239–1246.
- Mota, K.S., Dias, G.E., and Pinto, M.E. (2009) Flavonoids with gastro-protective activity. *Molecules* *14*:979–1012.
- Nduche, M. U., Edeoga, H. O., Omosun, G., and Nwankwo, D. (2015). Evaluation of the chemical composition of five Nigerian medicinal plants. *IOSR J. Pharm. Biol. Sc*, *10*(2), 27-31.
- Oluranti, A. C., Michael, U. O., Jane, U. O. C., and Ayembe, N. A. (2012). Ethno botanical studies of medicinal plants used in the management of Peptic ulcer disease in Sokoto State, North Western Nigeria. *Int. Res. J. Pharm. Pharmacol*, *2*(9), 225-230.
- Pradhan, D., Biswasroy, P., Singh, G., and Suri, K. A. (2013). Anti-ulcerogenic activity of Ethanolic Extract of *Cucumis sativus* L. against NSAID (Aspirin)-induced Gastric Ulcer in wistar albino rats. *International Journal of Herbal Medicine*.
- Rafaniello, C., Ferrajolo, C., Sullo, M. G., Sessa, M., Sportiello, L., Balzano, A., and Capuano, A. (2016). Risk of gastrointestinal complications associated to NSAIDs, low-dose aspirin and their combinations: Results of a pharmacovigilance reporting system. *Pharmacological research*, *104*, 108-114.
- Rao, C. V., and Vijayakumar, M. (2007). Protective effect of (+)-catechin against gastric mucosal injury induced by ischaemia-Reperfusion in rats. *Journal of Pharmacy and Pharmacology*, *59*(8), 1103-1107.
- Santhi, K., and Sengottuvel, R. (2015). Qualitative and Quantitative Phytochemical analysis of *Moringa concanensis* Nimmo. *Int. J. Curr. Microbiol. App. Sci.*, *5*(1): 633-640
- Sathya, V., Bharathidasan, R., Tamil, S.S., Solphia, R.N., Hakkiya, R, and Prabakaran, M. (2013). Quantitative, phytochemical analysis and in vitro antibacterial activity of *Bauchiniatomatosa*, L. *Journal of Natural Product Resources*, *3*(2),31-33.



- Scarpignato, C., and Hunt, R.H. (2010). Nonsteroidal antiinflammatory drug-related injury to the gastrointestinal tract: clinical picture, pathogenesis, and prevention. *Gastroenterol Clin North Am*, Vol.39, No.3, pp. 433-464.
- Trease, G. E, and Evans, W.C (1989). *Pharmacognsy*(13th ed) Baillere.Tindall London pp176-180.
- Udoh, F. V., Ekanem, A. P., and Ebong, P. E. (2011). Effect of alkaloids extract of *Gnetum africanum* on serum enzymes levels in albino rats. *Journal of Applied Pharmaceutical Science*, (Issue), 29-32.
- Urumarudappa, S. K. J., Rosario, S., Ravikanth, G., and Sukrong, S. (2023). A comprehensive review on *Saraca asoca* (Fabaceae)-Historical perspective, traditional uses, biological activities, and conservation. *Journal of Ethnopharmacology*, 116861.
- Wu, X., Huang, Q., Xu, N., Cai, J., Luo, D., Zhang, Q., and Liu, Y. (2018). Antioxidative and anti-inflammatory effects of water extract of *Acrostichum aureum* Linn. Against ethanol-induced gastric ulcer in rats. *Evidence-Based Complementary and Alternative Medicine*, 2018(1), 3585394.
- Zangeneh, M. M., Salmani, S., Zangeneh, A., Bahrami, E., and Almasi, M. (2019). Antiulcer activity of aqueous extract of leaves of *Mentha piperita* in Wistar rats. *Comparative Clinical Pathology*, 28, 411-418.
- Zhang, Z., Zou, Y. Y., Li, F. J., and Hu, C. P. (2011). Asymmetric dimethylarginine: A novel biomarker of gastric mucosal injury. *World Journal of Gastroenterology: WJG*, 17(17), 2178.
- Zhang, W., Lian, Y., Li, Q., Sun, L., Chen, R., and Lai, X. (2020). Preventative and therapeutic potential of flavonoids in peptic ulcers. *Molecules*. 25(20):4626.