



## Research Article

# *Digitaria exilis* Methanol Grain Extract Halts Acetaminophen Hepatotoxicity Onslaught Via Upregulation of Antioxidant Enzyme and Improved Hepatic Function in Wistar Rats

Moses Dele Adams

Clinical Biochemistry, Phytopharmacology and Biochemical Toxicology Research Laboratory (CBPBT-RL),  
Department of Biochemistry, Baze University, Abuja 900108, Nigeria

\*Corresponding author's Email: [moses.adams@bazeuniversity.edu.ng](mailto:moses.adams@bazeuniversity.edu.ng), [doi.org/10.55639/607.02010086](https://doi.org/10.55639/607.02010086)

### ARTICLE INFO:

#### Keywords:

*Digitaria exilis*,  
Acetaminophen,  
Hepatoprotective agent,  
Hepatocellular necrosis"  
Reduced glutathione.

### ABSTRACT

The exposure to most drugs presents with toxicological effect(s) which are detrimental to cells of the biological systems. This study therefore investigated the possible mechanism of hepatoprotection of *Digitaria exilis* methanol grain extract (DEMGE) against acetaminophen-induced hepatotoxic experimental models. Twenty-five rats (n=5) were divided into five groups. Animals in Group I (control) received distilled water (DW). Animals in Group II-V which were induced into hepatotoxicity (using 3 mg/kg body weight (BW) of acetaminophen intraperitoneally) were administered DW, 25 mg/kg BW of silymarin (reference drug), 250 and 500 mg/kg BW of DEMGE respectively. The animals were treated for 14 days followed by assessment of serum and liver biomarkers as well as liver histological examination. The phytochemical screening of DEMGE revealed flavonoids, saponins, alkaloids, anthraquinones and tannins. Acetaminophen which significantly ( $p < 0.05$ ) increased serum levels of MDA and  $H_2O_2$  and liver activities of ALP, ALT and AST, lowered ( $p < 0.05$ ) the levels of SOD, CAT, GSH and TP when compared with the sham control. Treatment of the hepatotoxic animals with DEMGE normalized these observations when compared with the DW treated animals, in a manner not comparable with silymarin. Liver histology of the DW treated hepatotoxic animals which showed fat degenerated liver parenchyma, acute hepatocellular necrosis, central vein inflammation, severe hepatocyte vacuolation, fat infiltration (steatosis), mild aggregate of inflammatory cell infiltration and degenerated liver sinusoids, were normalized by DEMGE. The study suggests that *D. exilis* is a potential hepatoprotective agent against acetaminophen-induced hepatic injury through reduced oxidative stress, improved hepatic function, and reduced hepatocellular necrosis.

Corresponding author: Moses Dele Adams Email: [moses.adams@bazeuniversity.edu.ng](mailto:moses.adams@bazeuniversity.edu.ng)  
Department of Biochemistry, Baze University, Abuja 900108, Nigeria

## INTRODUCTION

Hepatotoxicity, (also known as toxic liver disease or toxic hepatitis) is defined as liver damage via exposure to a toxic substance, such as a medication, chemical, or supplement. The liver is susceptible to toxicity because it metabolizes many substances, and this process can lead to liver hepatotoxic onslaught and impaired function (Tiwari *et al.*, 2025). This onslaught had been reported to pose a global hepatotoxic burden (Devarbhavi *et al.*, 2023; Wu *et al.*, 2024). Hepatotoxicity is caused by many unauthorized over-the-counter prescriptions/medications; ingestion of some herbal products and dietary supplements and toxins from exposure to chemicals/ono-infectious agents. The indiscriminate use of medications like acetaminophen has been reported to cause hepatotoxicity. Acetaminophen (paracetamol) is an organic compound chemically known as N-(4-hydroxyphenyl)acetamide or p-acetamidophenol (Roy *et al.*, 2024; Gan *et al.*, 2025). Acetaminophen works mainly in the brain through the inhibition of central cyclo-oxygenase (COX-1 and COX-2) in peripheral tissues; activation of serotonergic pain pathway; activation of cannabinoid/transient receptor potential vanilloid 1 (TRPV1) receptors via an active metabolite of paracetamol (AM404), and hypothalamic temperature (antipyretic) regulation thereby lowering its thermoregulatory set point evidenced by pain-relieving and anti-inflammatory effects (Ayoub, 2021). Hepatotoxicity is characterized by symptoms including jaundice (yellowing of the skin and whites of the eyes), itching, pain in the upper right part of the abdomen, fatigue, loss of appetite, nausea/vomiting, rash, fever, dark urine. Laboratory diagnosis of hepatotoxicity involve the assay of hepato-markers like LFTs: ALP, AST, ALT among others (Thakur *et al.*, 2024).

Treatment options for hepatotoxicity include stoppage of predisposing agent (drug, toxin, or alcohol); targeted treatments using natural compounds/herbs like curcumin; silymarin; glycyrrhizin; resveratrol; ginseng; garlic; green tea extracts; artichoke leaf; dandelion; schisandra fruit; N-acetylcysteine (NAC) for acetaminophen overdose; L-carnitine for valproic acid overdose; corticosteroids for management of immune-mediated hepatotoxicity; symptomatic treatments like bile acid sequestrants against cholestasis and liver transplant. Vitamins, minerals and other compounds like

adenosylmethionine (SAM); glutathione (GSH); choline; vitamins C and E; zinc and selenium are also potent liver protective candidates. These treatment options have side effects (mild gastrointestinal upset [nausea, vomiting, abdominal pain, loose stools, or diarrhea], skin reactions [Pruritus/itching, rash, or erythema/redness] as well as general systemic effects like fatigue, somnolence/sleepiness, or headaches) (David and Hamilton, 2010) which are overcome by medicinal plants out of which *Digitaria exilis* is one.

*Digitaria exilis* is classified to the family *Poaceae* and it is called *Hungry Rice* in English. *D. exilis* grain is popularly called by Nigerian names like *Acha* (Hausa), *Suru* (Yoruba) and *Achara* (Igbo). It is an annual and erect herbaceous plant reaching a height of 20 -70 cm (Ballogou *et al.*, 2013). The ears of the plant have three-five narrow part ears that are up to 13cm long. The spikelets are composed of fertile and sterile flowers which eventually give rise to a fonio plant. The grain is a caryopsis that is flanked by husks and glumes. The grain has a small size of 1.5mm. The grain naturally exists in colours like white, black, yellow and purple (Heuze *et al.*, 2019; Adams *et al.*, 2023). It is mostly grown in Nigerian States like Borno, Jigawa, Taraba, Kaduna, Plateau, Yobe, Nasarawa, Niger, Adamawa, Bauchi, Kano and Kebbi, among others, where the grains are used to prepare a native delicacy locally called 'Gwate' (porridge in Hausa), others are cake, soup, flour meal and local beverage drink ('Kunu' in Hausa) (Adams and Yakubu, 2020).

The modulation (upregulation and downregulation) of examined biomarkers (like total protein, MDA, GSH, SOD, AST, ALT, ALP or other biomolecules) and the actual pathways they belong, especially when these biomarkers show reduced activity, often reflect the probable pathway in terms of the ability of signalling reductive function of the pathway in addition to indicating how biomarkers pinpoint changes in complex biological systems. Previous studies on *Digitaria exilis* grains include a study by Adams *et al.* (2025a) who reported the inhibitory property of phytochemicals from *Digitaria exilis* aqueous grain extract against Type II diabetes mellitus via gas chromatography-mass spectroscopy (GC-MS), induced fit molecular docking as well as absorption, distribution, metabolism, excretion and toxicity (ADMET) analysis. Nweke *et al.* (2025) studied the effect of ethanol extract of *Digitaria exilis* on the hepatic health and body

weight of diabetic rats. Adams *et al* (2023) examined the anti-constipation property of polyphenol-rich extract of *D. exilis* grains. In a study by Umerah and Asouzu (2023) on modulatory expression of lipogenic activity by malted hungry rice flour, they suggested that *Digitaria exilis* exhibited anti-obesity effect. Adams *et al* (2025b) examined the contraceptive property of *Digitaria exilis* grain extract using molecular docking and histopathology with an observation of interference with steroidogenesis at ovarian level. Olu-Owolabi *et al* (2014) looked at the comparison of functional properties between native and chemically modified starches from Acha (*Digitaria* Stapf) grains. John *et al* (2022) noticed that two excipients of *Digitaria exilis* had different effects on the size and morphology of the nanoparticles and controlled the release of drug from the nanoparticles. Based on the available information available, none of the above studies have examined the liver protecting mode of action of *Digitaria exilis* grains in drug-induced hepatocellular injury, creating a research gap. This study therefore assessed the probable hepatoprotective mechanism of action of *Digitaria exilis* methanol grain extract in acetaminophen-induced liver damage.

## MATERIALS AND METHODS

### *Plant and its authentication*

The plant material collected from local vendors at Gwagwalada, Abuja was identified and confirmed at the Plant Biology Unit, University of Ilorin, where a Plant Identifier (I.U.V. No. 007) was assigned in the Herbarium.

### *Experimental animals*

Albino rats of Wistar strain ( $124.85 \pm 3.57$  g) was collected from the Animal House of the University of Abuja Veterinary Hospital. The animals which were placed in metallic compartment stationed in properly ventilated cage (Heat: 28–31°C; Light: 12 hours; Humidity: 50–55%) were allowed to feed on rat pellet (Chidex Feeds, a product of Chidex Poultry Farm, Jikwoyi, Abuja, Nigeria) and clean water.

### *Assay kits, drugs and chemicals*

The assay kits used in the study were brands from Randox Laboratories Ltd., Co-Antrim, London. Acetaminophen was procured from Micro Labs Limited 92, Sipcot, Hosur-635126, India while silymarin was obtained from Drug Field Pharmaceuticals Ltd, lynson Chemical Avenue, Km 38, Lagos-Abeokuta Expressway, Sango-Ota, Ogun State, Nigeria. Other chemicals used in the study are of analytical standard.

### *Ethical approval*

The ethical clearance for this study was obtained from the University of Abuja Ethics Committee on Animal Use with a reference number (UAECAU/2024/023).

### *Preparation of Digitaria exilis methanol grain extract*

The grains of *D. exilis* was spread open to dry at room temperature before grinding with an electric blender (Kenwood, Model KT-750, England, UK). A known amount of the powdered grain (2000 g) was extracted in 20 L of methanol for 72 h at 26 °C. The solution was filtered with Whatman No. 1 filter paper (Maidstone, UK) and the resulting filtrate was concentrated in a Rotary Evaporator (Model: BH-45A, Shanghai Ya Rong Biochemistry Instrument Factory, China). The filtrate was then dried in a steam bath (Model: NL-450S, NEWLIFE® Medical Instrument, England) to yield 28.35 g extract (DEMGE). The resulting ethanol extract was redissolved in distilled water to give the doses of 250 and 500 mg/kg BW that was used in the study. The 250 mg/kg BW correspond to a handful of the plant powder taken to be consumed by an adult of 70 kg as a remedy against hepatotoxic damage. The 500 mg/kg BW which is double of the other dose was used to account for cases of ‘toxicity/abuse’ by users.

### *Screening of secondary metabolites in Digitaria exilis methanol grain extract*

The phytochemical screening of *Digitaria exilis* methanol grain extract (DEMGE) was carried out by adopting the procedure previously described by Trease and Evans (1983).

### *Animal grouping and extract administration*

The animals were acclimatized for two weeks before the commencement of the experiment. The rats were divided into five groups of five each as follows:

Group 1: Healthy rats + DW

Group 2: Hepatotoxic rats + DW

Group 3: Hepatotoxic rats + Silymarin (25 mg/kg BW)

Group 4: Hepatotoxic rats + 250 mg/kg BW of DEMGE

Group 5: Hepatotoxic rats + 500 mg/kg BW of DEMGE

The induction of hepatotoxicity in the animals by acetaminophen (3 mg/kg BW) followed the previous study by Iroanya *et al* (2018). Extract administration lasted for 14 days followed by the assessment of related serum and liver biomarkers as well as liver histopathological examination.

### *Preparation of serum and liver supernatant*

The preparation of supernatants was done by adopting the procedure of Adams and Eze (2022). As detailed therein, under anaesthesia

with the use of diethyl ether, the fur hair of the animals was carefully removed from the neck region, after which the jugular veins were cut with a sterilized blade allowing collection of whole blood cells into plain blood sample container. The blood cells were centrifuged at 1500 *g* for 10 min with a BioBase Laboratory Centrifuge (Model BD900B, BioBase Scientific {Shandong} Co., Ltd., Jinan, Shandong, China). The serum (supernatant) was carefully decanted into a new sample bottle, which was used for the determination of serum total protein and some antioxidant biomarkers (MDA, SOD, CAT and GSH). Immediately after this, the rats were incised to harvest the liver. A portion of the liver was blotted independently, homogenized, and centrifuged to obtain the liver supernatants which was used for the determination of marker enzyme activity (ALP, AST and ALT). The other portion of the liver was fixed in 10% formaldehyde for histological examination.

#### **Determination of related antioxidant biomarkers**

The protocol previously described by Tsikas (2017); Camera *et al* (2001); Hamza and Hadwan (2020); Kanioura *et al* (2024); Fayazi (2019) was adopted in this study for the determination of the hepatic level/activity of MDA, GSH, CAT, SOD, H<sub>2</sub>O<sub>2</sub> respectively.

#### **Determination of some related markers of hepatocellular damage**

The determination of liver activities of AST and ALT; ALP; as well as serum protein level was

done by adopting the procedure of Reitman and Frankel, (1957); Wright *et al* (1972); and Gornall *et al* (1949) respectively.

#### **Histological examination of the liver**

The liver of the rats was fixed in 10% (v/v) formaldehyde, dried with preferred grades of ethanol (75%, 85%, and 95% v/v), cleaned in xylol, and dipped in paraffin wax (melting point 57 °C). Each section of the liver was then produced following the protocol outlined by Rocha-Pereira *et al* (2019) and stained using hematoxylin/eosin (H&E). The histological slides were observed under a light LED camera Magnifier (MIGHTEX, Model: EZ42, Pleasanton, CA 94566, USA). Micrographs representing the liver was captured at x400 via Canon! Microsoft Image Capturing Software (Model: Capture Strength A3600, Germany).

#### **Statistical analysis of raw data obtained**

The protocols detailed in one-way ANOVA and Duncan multiple Range Test were used to statistically analyze the results obtained from the study (n=5). Statistical Product and Service Solution, SPSS version 23 was used to determine significant difference at  $p < 0.05$ .

### **RESULTS**

Phytochemical screening of *Digitaria exilis* methanol grain extract revealed the presence of flavonoids, saponins, alkaloids, anthraquinones and tannins. Phytochemicals including phlobatannins, steroids, terpenoids, cardenolides and cardiac glycosides were absent in the plant extract (Table 1).

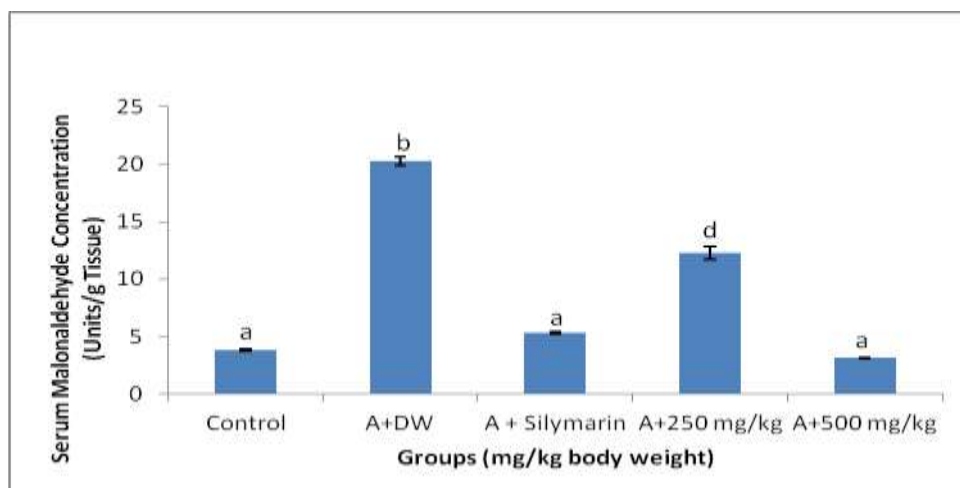
**Table 1:** Phytochemicals in *Digitaria exilis* methanol grain extract

Phytochemical	Observation
Alkaloids	+
Tannins	+
Phlobatannins	–
Flavonoids	+
Saponins	+
Steroids	–
Terpenoids	–
Anthraquinones	+
Cardenolides	–
Cardiac glycosides	–

**Key:** + = present; – = absent

The administration of acetaminophen substantively ( $p < 0.05$ ) heightened the concentration of serum malondialdehyde when matched with the sham control (SC). However, the administration of the 250 and 500 mg/kg body weight (BW) of *Digitaria exilis* methanol

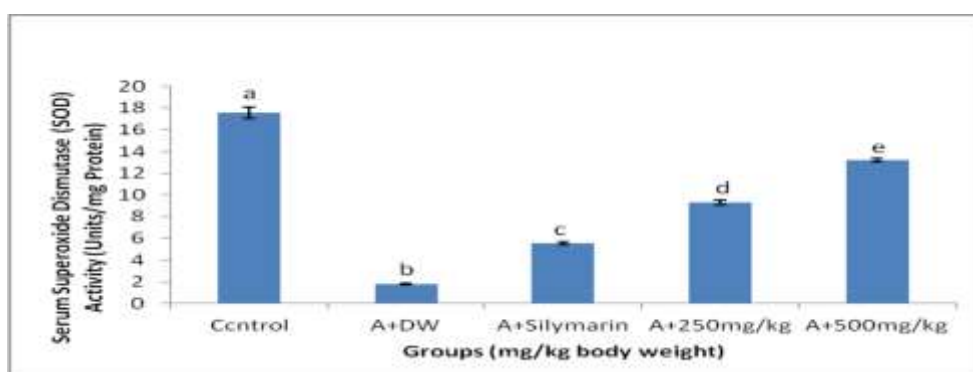
grain extract (DEMGE) sufficiently ( $p < 0.05$ ) lowered serum MDA concentration. The 500 mg/kg BW of DEMGE produced serum MDA values that was comparable ( $p > 0.05$ ) with those of silymarin (reference drug) and the SC (Figure 1).



**Figure 1:** Serum malondialdehyde (MDA) concentration following oral administration of methanol grain extract of *Digitaria exilis* in acetaminophen-treated hepatotoxic rats  
**A=** Acetaminophen; **DW=** Distilled Water

The induction of hepatotoxicity with acetaminophen significantly ( $p < 0.05$ ) lowered the serum activity of SOD when liken with the SC. The administration of DEMGE at all doses significantly ( $p < 0.05$ ) elevated serum SOD

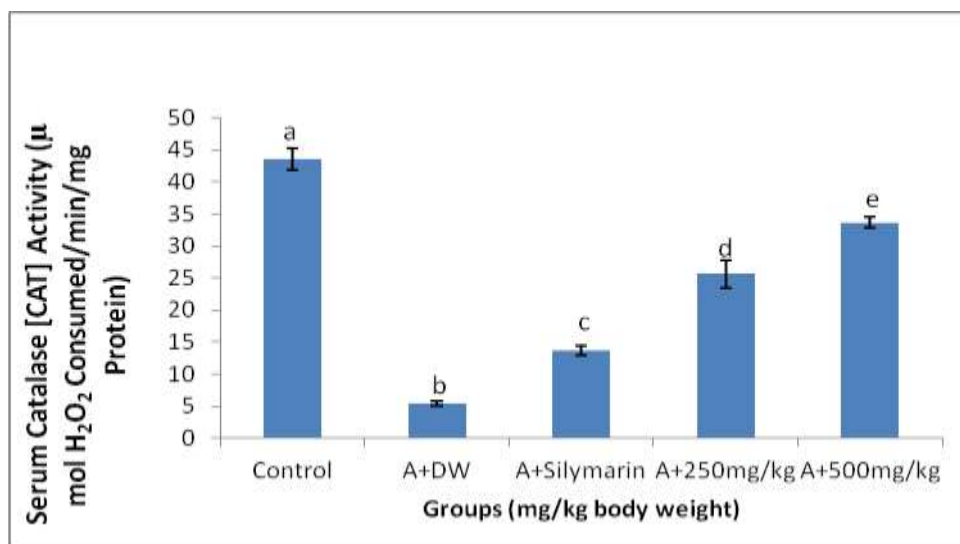
activity when liken with the DW treated hepatotoxic animals. The activity of both doses of DEMGE occurred in manner that was not comparable with that of silymarin (Figure 2).



**Figure 2:** Serum superoxide dismutase (SOD) activity following oral administration of methanol grain extract of *Digitaria exilis* in acetaminophen-treated hepatotoxic rats  
**A=** Acetaminophen; **DW=** Distilled Water

The administration of acetaminophen statistically ( $p < 0.05$ ) lowered serum catalase activity when matched-up with the placebo. Treatment of the hepatotoxic rats with both doses of DEMGE (250 and 500 mg/kg BW)

substantially ( $p < 0.05$ ) raised the activity of serum catalase in a dose dependent manner when compared with the DW treated hepatotoxic animals. The activity of the extract was higher than that of silymarin (Figure 3).

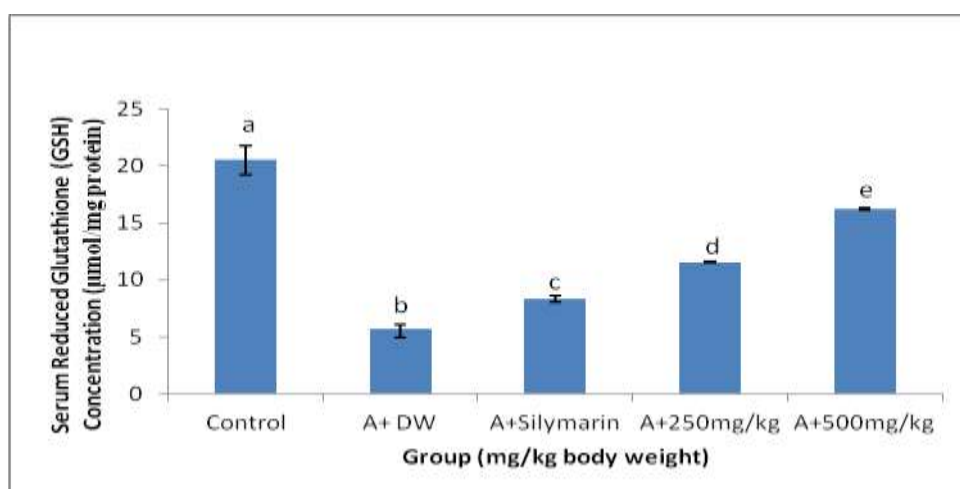


**Figure 3:** Serum catalase (CAT) activity following oral administration of methanol grain extract of *Digitaria exilis* in acetaminophen-treated hepatotoxic rats

A= Acetaminophen; DW= Distilled Water

The induction of acetaminophen significantly ( $p < 0.05$ ) lowered the concentration of serum GSH when liken with the sham control. The two dose levels of DEMGE however showed a dose dependent raise ( $p < 0.05$ ) in the level of

serum GSH when matched-up with the DW treated hepatotoxic animals. The activity of the extract doses for serum GSH did not compare well with that of silymarin (Figure 4).

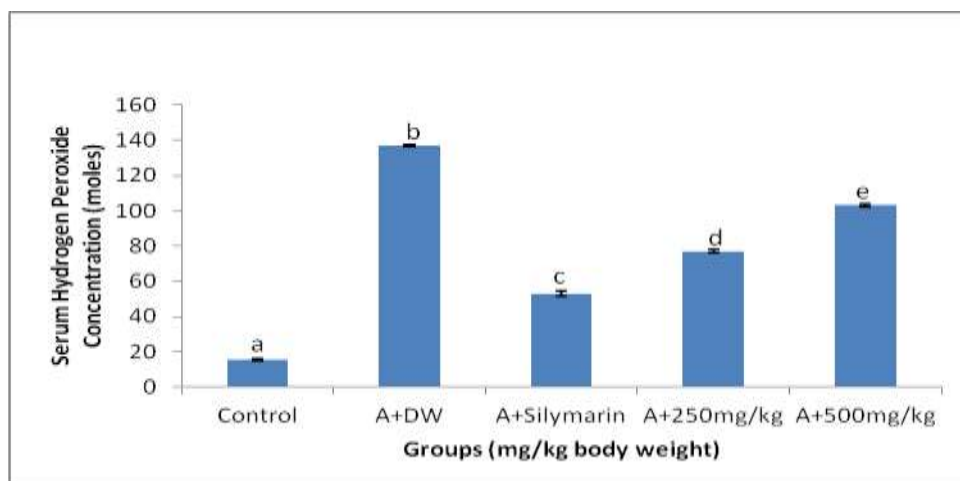


**Figure 4:** Serum reduced glutathione (GSH) concentration following oral administration of methanol grain extract of *Digitaria exilis* in acetaminophen-treated hepatotoxic rats

A= Acetaminophen; DW= Distilled Water

The induction of hepatotoxicity by acetaminophen significantly ( $p < 0.05$ ) raised the level of hydrogen peroxide (H<sub>2</sub>O<sub>2</sub>) when liken with the sham control. However, the treatment of the hepatotoxic animals with all

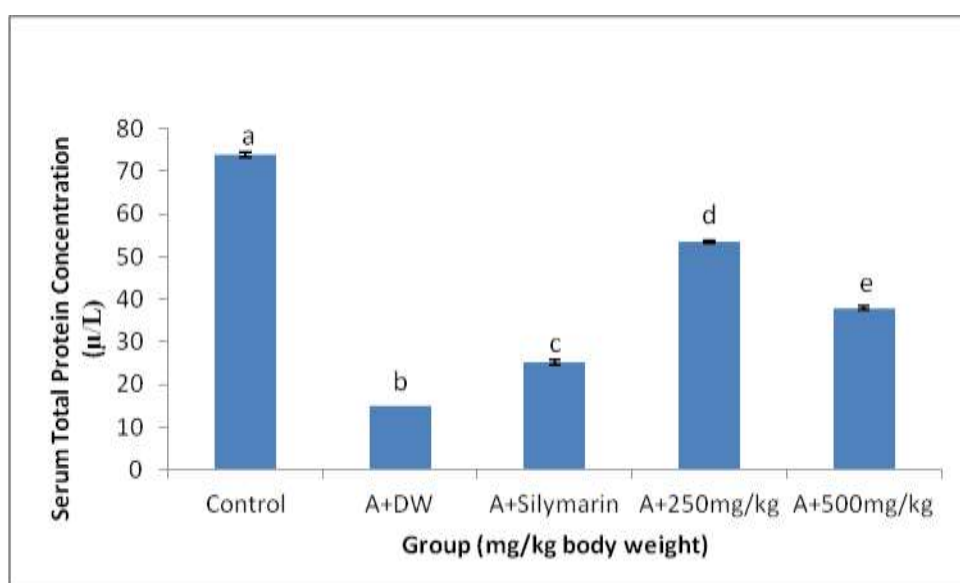
doses of DEMGE substantially ( $p < 0.05$ ) lowered serum H<sub>2</sub>O<sub>2</sub> concentration when liken with the DW treated hepatotoxic animals. The activity of the extract was not comparable with that of silymarin (Figure 5).



**Figure 5:** Effect of methanol grain extract of *Digitaria exilis* on serum hydrogen peroxide ( $H_2O_2$ ) concentration in acetaminophen-treated hepatotoxic rats  
**A=** Acetaminophen; **DW=** Distilled Water

Administration of acetaminophen significantly ( $p<0.05$ ) lowered serum protein level when compared with the sham control. In contrast, all doses of DEMGE glaringly ( $p<0.05$ )

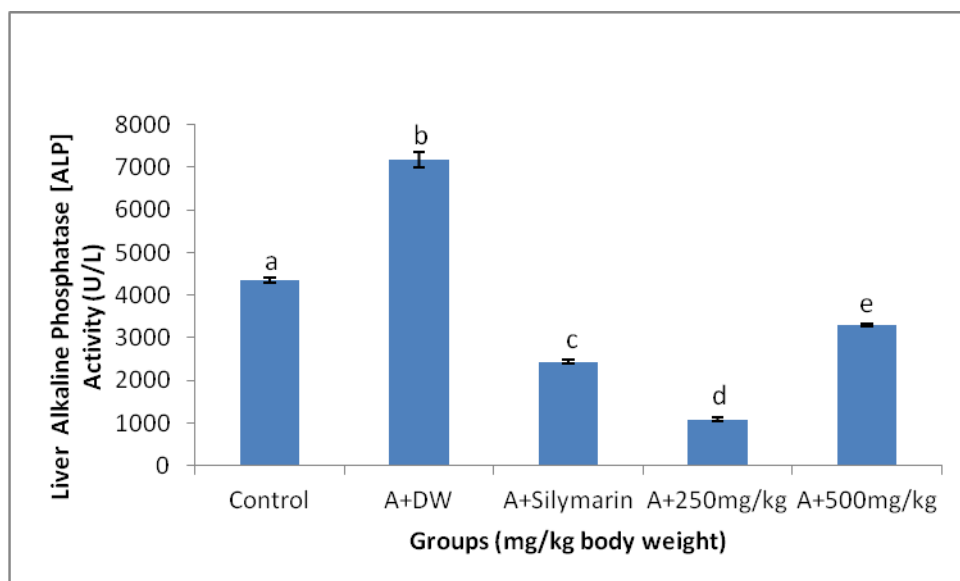
increased serum protein concentration in a manner that was not comparable with that of silymarin (Figure 6).



**Figure 6:** Effect of methanol grain extract of *Digitaria exilis* on serum total protein concentration in acetaminophen-treated hepatotoxic rats  
**A=** Acetaminophen; **DW=** Distilled Water

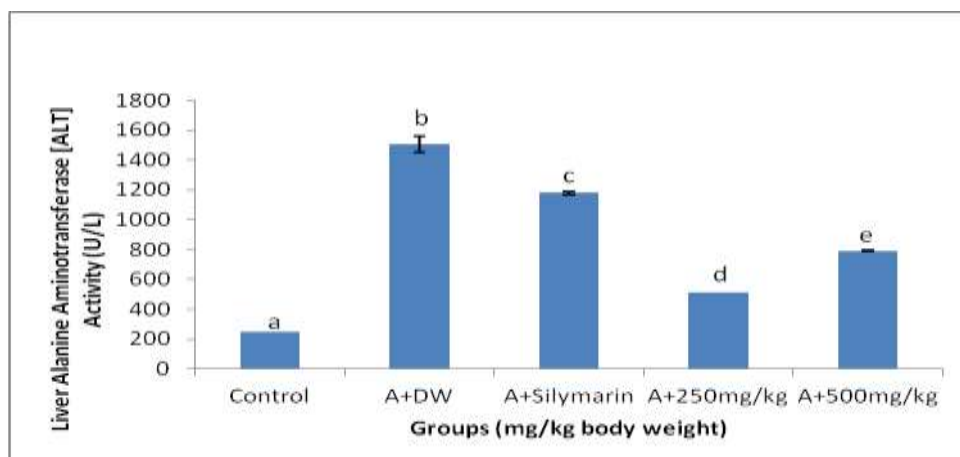
Treatment of the animals with acetaminophen notably ( $p<0.05$ ) elevated the activity of ALP in the liver of the animals when compared with the placebo. However, the 250 and 500 mg/kg BW of DEMGE statistically ( $p<0.05$ ) lowered

liver ALP activity when matched-up with the hepatotoxic animals treated with DW. The effect of the extract doses did not compare well with that of silymarin (Figure 7).



**Figure 7:** Liver alkaline phosphatase (ALP) activity after oral administration of methanol grain extract of *Digitaria exilis* in acetaminophen-treated hepatotoxic rats  
A= Acetaminophen; DW= Distilled Water

Acetaminophen significantly ( $p < 0.05$ ) heightened liver ALT activity when liken with sham control while all extract doses reduced the liver ALT activity. The activity of the extracts occurred in a manner that was not comparable with that of silymarin (Figure 8).

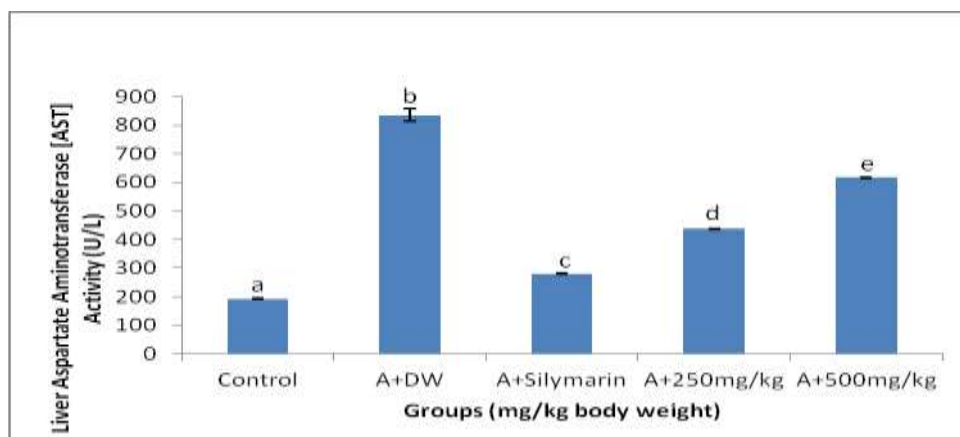


**Figure 8:** Liver alanine aminotransferase (ALT) activity after oral administration of methanol grain extract of *Digitaria exilis* in acetaminophen-treated hepatotoxic rats  
A= Acetaminophen; DW= Distilled Water

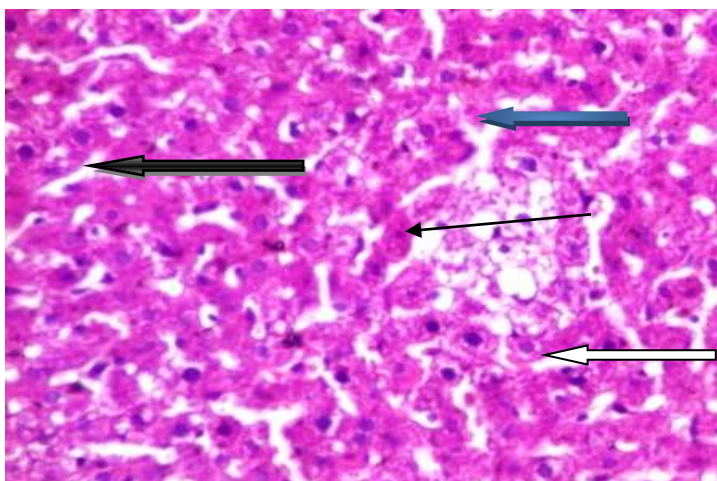
The induction of hepatotoxicity by acetaminophen substantively ( $p < 0.05$ ) elevated liver AST activity when liken with the sham control. Treatment of the hepatotoxic animals with all doses of the extract

significantly ( $p < 0.05$ ) lowered the liver AST activity in a dose dependent manner when compared with the DW treated hepatotoxic animals (Figure 9).

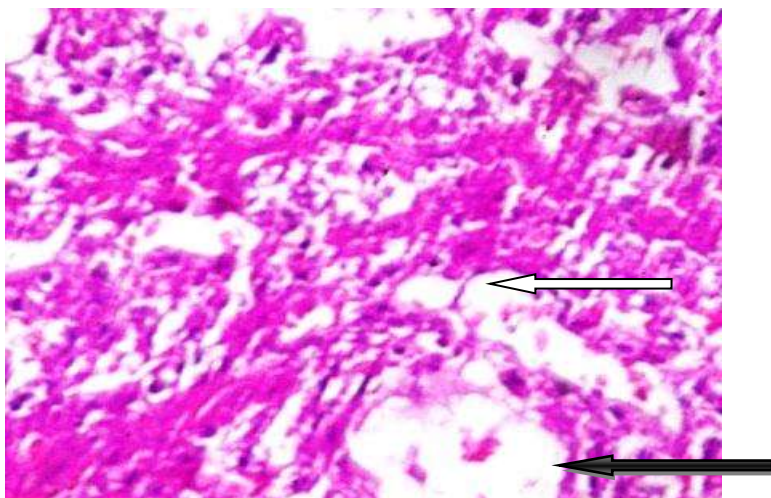




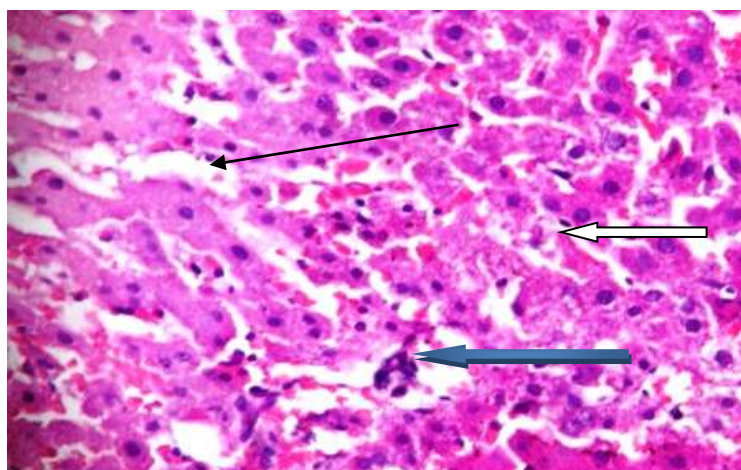
**Figure 9:** Effect of methanol grain extract of *Digitaria exilis* on liver aspartate aminotransferase (AST) activity in acetaminophen-treated hepatotoxic rats  
**A=** Acetaminophen; **DW=** Distilled Water



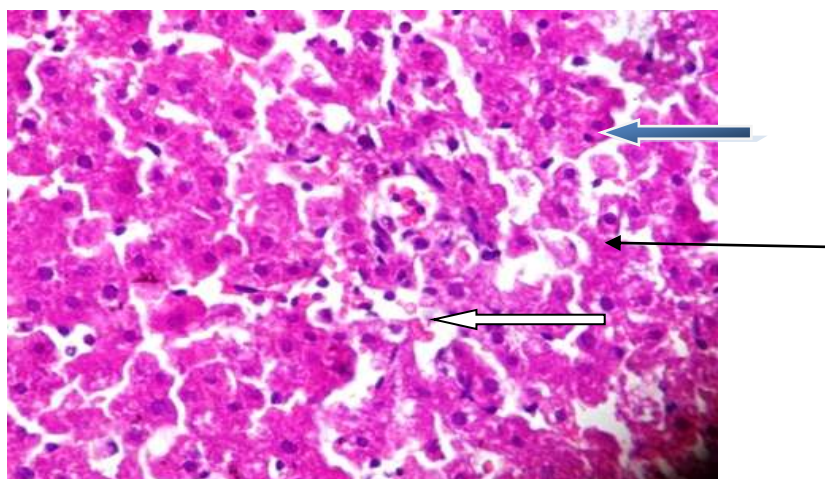
**Figure 10:** Photomicrograph of representative of the liver of healthy rats that received distilled water (x400 H&E)



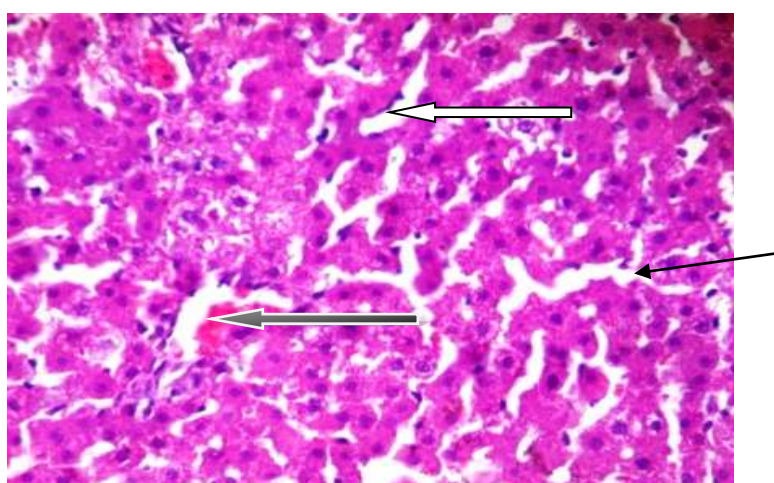
**Figure 11:** Micrograph of representative of the liver of hepatotoxic rats (acetaminophen) that received distilled water (x400 H&E)



**Figure 12:** Histological section of representative of the liver of hepatotoxic rats treated with silymarin (standard drug) (x400 H&E)



**Figure 13:** A cross-section of representative of the liver of hepatotoxic rats that received 250 mg/kg body weight of methanol grain extract of *Digitaria exilis* (x400 H&E)



**Figure 14:** Histological section of representative of the liver of hepatotoxic rats treated with 500 mg/kg body weight of methanol grain extract of *Digitaria exilis* (x400 H&E)

In Figure 10, the cross section of the liver of animals that received distilled water (DW) revealed normal central venules without congestion (white arrow). The liver parenchyma showed focal areas of generative liver cells by aligned fat infiltration (black arrow). The morphology of several other hepatocytes appeared normal (blue arrow) while the sinusoids appeared normal and un-infiltrated with fat (slender arrow). In Figure 11, the histological section of the liver of acetaminophen-induced hepatotoxic rats that received DW showed a deranged central venule with congestion (white arrow), with very poor liver architecture. The liver parenchyma was degenerated by fat and necrosis (black arrow), the hepatocytes cytoplasm showed severe infiltration by fat (severe steatosis). In Figure 12, the histoarchitecture of hepatotoxic rats that received silymarin showed normal central venules with moderate congestion (white arrow). The liver parenchyma showed focal area of hepatocytes cytoplasm with mild infiltration by fat cells (moderate steatosis) (blue arrow) while the sinusoids was observed with mild infiltration (slender arrow).

In Figure 13, the micrograph of hepatotoxic rats that received 250 mg/kg BW of DEMGE showed moderately congested venules without hepatocellular congestion (white arrow). The morphology of the hepatocytes showed mild steatosis (blue arrow) while the sinusoids appeared normal without fat infiltration (slender arrow). In Figure 14, the histological section of representative of hepatotoxic rats that received 500 mg/kg BW of DEMGE showed normal central venules without congestion (white arrow). The liver cells (hepatocytes) were seen with mild degeneration by fat as well as their cytoplasm with slight infiltration (moderate steatosis) (blue arrow). The sinusoids appear normal with no infiltration by fat (slender arrow).

## DISCUSSION

Phytochemicals derived from medicinal plants play vital role in the mechanism of hepatoprotection against hepatocellular damage due to their antioxidant properties which help in mitigating against liver injury caused by chemical agents, drugs, toxins, alcohol, and viruses (Kim *et al.*, 2025). Major phytoconstituents like flavonoids, anthraquinones, tannins, flavonoids and saponins might be responsible for these hepatoprotective effects of plant extract. The flavonoid contained in *D. exilis* operate as natural antioxidants that

act by scavenging free radicals thereby blocking oxidative stress, and reducing lipid peroxidation, which are major contributors to liver cell damage (Foghis *et al.*, 2023). Alkaloids helps in enhancing the body's natural endogenous antioxidant systems such as superoxide dismutase (SOD), catalase (CAT), and glutathione peroxidase (GP<sub>x</sub>), thus boosting cellular defense. Saponins exhibit anti-inflammatory effects via reduction in liver inflammation by suppressing pro-inflammatory cytokines like TNF- $\alpha$  and IL-6 (Qadri *et al.*, 2025). Tannins are involved in the modulation of apoptosis and regenerative role thus protecting the hepatocytes from apoptosis (programmed cell death) while promoting liver cell regeneration after injury (Subramanya *et al.*, 2018; Babyvanitha *et al.*, 2023).

Malondialdehyde (MDA) is a reactive aldehyde and a key byproduct of lipid peroxidation, the damaging process where free radicals attack fats in cells, making it a widely used biomarker for oxidative stress and hepatocellular damage. The high MDA level observed in this study may signal increased oxidative stress, linked to hepatocellular damage. The reduced serum MDA concentration in this study may indicate the antioxidant properties of the plant which could have occurred via actively inhibiting the process of lipid peroxidation, a key mechanism of liver cell damage. The reduced serum MDA level by DEMGE could have also occurred by neutralization of free radical generation, inhibition of lipid peroxidation, prevention of MDA formation, maintenance of cell membrane integrity against leakage of liver enzymes into the bloodstream as well as enhancement of the body's antioxidant defense system (Ojo *et al.*, 2024).

Hydrogen peroxidase (H<sub>2</sub>O<sub>2</sub>) is a reactive oxygen species that predispose to liver oxidative stress. It is a compound that possesses an oxygen-oxygen single bond. It decomposes slowly into water and elemental oxygen when exposed to light, and rapidly in the presence of organic or reactive compounds. The high H<sub>2</sub>O<sub>2</sub> activity following the injection of acetaminophen suggest its ability to induce hepatocellular injury. However, the reduced H<sub>2</sub>O<sub>2</sub> by DEMGE, in this study, indicates the ability of the extract to directly scavenge/reduce hydrogen peroxide activity, chelate metal ions that catalyze H<sub>2</sub>O<sub>2</sub>-damaging reactions, and modulate the activity of natural antioxidant enzymes (de-Oliveira *et al.*, 2021).

Superoxide dismutase (SOD) is a powerful antioxidant enzyme that converts harmful superoxide radicals into oxygen and hydrogen peroxide. The low serum SOD activity signifies hepatotoxicity and the ability of acetaminophen to induce liver damage. The increased serum SOD activity by DEMGE, in the present study, indicates the ability of the plant extract to directly activate endogenous antioxidant pathways and scavenge free radical formation. Also, the direct antioxidant and free radical scavenging activity of the phytochemical contents of DEMGE, could occur via neutralization of reactive oxygen species (ROS) by scavenging superoxide anions where SOD catalyzes the dismutation of the harmful superoxide anion radical ( $O_2^-$ ) into hydrogen peroxide ( $H_2O_2$ ) and oxygen ( $O_2$ ) (Al-Sheddi *et al.*, 2015). This is followed by downstream neutralization where the  $H_2O_2$  produced by SOD is then quickly converted into harmless water and oxygen by other antioxidant enzymes like catalase and glutathione peroxidase. Then, it terminates with the inhibition of lipid peroxidation by the removal of free radicals, where DEMGE helps to prevent lipid peroxidation, a key mechanism of cell membrane damage caused by hepatotoxins. This maintains the structural integrity of hepatocytes (liver cells) (Zhou *et al.*, 2021).

Catalase (CAT) is an important antioxidant enzyme found in almost all living organisms that protects the cell from oxidative liver damage. It is involved in catabolism of hydrogen peroxide ( $H_2O_2$ ) to water and oxygen. This reaction is vital as it prevents the build-up of ROS, which can predispose to liver damage. In this study, the DEMGE demonstrated hepatoprotective functions and increased serum catalase (CAT) activity mainly via the activation of endogenous antioxidant defense pathways majorly by acting as direct free radical scavengers via its direct antioxidant and scavenging ability (Alkinani *et al.*, 2021; Agada *et al.*, 2024).

Reduced glutathione (GSH) is the active antioxidant form of glutathione, a tripeptide made of three amino acids that is crucial for protecting cells from oxidative damage, supporting detoxification, and boosting the immune system. It neutralizes free radicals, aids in the breakdown of toxins, and is important for cellular maintenance, including DNA synthesis and repair. Reduced glutathione is also used in supplements for its potential benefits in skin health, liver function, and immune support. The increase in serum GSH by DEMGE, in this study, may indicate that the

plant extract majorly facilitates glutathione (GSH) activity and provide hepatoprotection through either of the two main mechanisms: activating the Nrf2 signalling pathway to increase *de novo* synthesis of GSH, and directly influencing the enzymes involved in GSH synthesis and recycling (Garcia-Cortes and Garcia-Garcia, 2022). The increased serum GSH concentration of DEMGE may also be adduced to possession on significant free radical scavenging activity by the plant extract which directly neutralize reactive oxygen species (ROS) and reactive metabolites, thus reducing the initial oxidative stress and subsequent depletion of the existing cellular GSH pool (Mittal *et al.*, 2025).

Liver function assays are laboratory diagnosis performed to confirm the functional status of the hepatocytes. A serum total protein test is capable of suggesting potential liver disorder. This is because, the liver is the primary site of biosynthesis of most serum proteins, so abnormal levels can point to liver disease. Therefore, the elevated serum total protein concentration, in this study, may be adduced to the ability of the liver to adequately synthesize useful concentration of protein required for biological processes (Hayden and Heyningen, 2001; Okere *et al.*, 2014).

The determination of enzyme activity in tissues and body fluids can provide useful information on disease diagnosis, extent of liver disease and general organ damage. Alkaline phosphatase is an ectoenzyme of the hepatocyte's plasma membrane. It is one of the enzymes used to assess the integrity of cells following the administration of chemical compounds. It also plays an important role in maintaining cell membrane permeability. Alterations from the normal concentration range of enzyme activity in certain cells can also indicate functional toxicity, which can be compared with structural toxicity for better inference. The lowered liver alkaline phosphatase (ALP) activity by DEMGE suggests hepatoprotective (liver-protecting) effects, evidenced by reduced liver damage, lowered inflammatory state, and improved antioxidant defense (Al-Nadaf *et al.*, 2025).

The aminotransferases considered in the present study are useful biomarkers of liver injury and can be used in assessing possible damage in the liver. Aminotransferases occupy a central position in the metabolism of amino acids and biochemical regulation of intracellular amino acid pool. The reduced liver AST and ALT activity by the 250 and 500 mg/kg BW of DEMGE may signify the ability of the plant



extract to bring about reduced liver enzyme leakage (as a high liver AST and ALT mean liver cell injury), thus protecting the biomembranes and preventing leakage of the enzyme molecule into the blood (Nisar *et al.*, 2025). Other possible mechanism of action of DEMGE could be by its robust antioxidant activity with the extract reducing the harmful free radical species (ROS) that cause liver damage and boosting the synthesis of natural antioxidants (CAT, SOD, GSH, among others), thus protecting the hepatocytes. Furthermore, the extract could have acted by improving the flow along the bile duct proliferation, which ultimately reduce accumulation of bile and also lower the liver activity of AST and ALT (Cheng *et al.*, 2024). Histological examination of tissues serves as complementary evidence to validate results of functional indices and enzyme studies by revealing possible distortion/damage to the normal histoarchitecture of the tissues. The normal histological section of the liver in the sham control animals might be due to an inherent defense mechanism exerted by the hepatic cells (Innih *et al.*, 2025). The appearance of acute hepatic necrosis, deranged central venules, degenerated liver parenchyma and severe fat infiltration sequel to acetaminophen injection, might be adduced to the ability of acetaminophen to induce hepatotoxicity as evidenced by derangement hepatocyte and observed poor liver architecture (Neyrinck, 2004; El-wenssemy, 2008; khudhair *et al.*, 2025). It may also be indicative of degenerated liver tissue and loss of structural integrity of the liver (Adams *et al.*, 2017). The mild effect of silymarin (reference drug) and DEMGE (at 250 and 50 mg/kg BW) on the liver histoarchitecture might be adduced to the selective effect of the drug and plant extract (DEMG) as evidenced by slight distortion of the central venule with mild congestion, moderate derangement of the liver parenchyma, sinusoids as well as mild infiltration by fat cells in the liver (Kodariah *et al.*, 2022; Jebese-Uduru *et al.*, 2025). The ability of the plant extract (DEMG) to normalize the hepatotoxic damage caused by acetaminophen induction, suggest that the plant extract, at the doses investigated in this study, offered protection to the liver against acetaminophen hepatotoxicity.

## CONCLUSION

The study showed that *D. exilis* grains lowered the elevated acetaminophen hepatotoxic damage by reducing serum oxidative stress markers, liver enzyme markers and normalizing the damaged liver histoarchitecture. The observed abilities of

the plant extract may be attributed to the presence of phytochemicals which are involved in the mechanism of hepatoprotection. These abilities confer potential hepatoprotective role on the *D. exilis* grains against acetaminophen-induced hepatic injury.

## ACKNOWLEDGEMENTS

The technical efforts of the laboratory staff of the Biochemistry Department, Baze University Abuja, Nigeria is well appreciated.

## REFERENCES

- Adams, M.D. and Eze, E.D. (2022). *Borassus aethiopum* (Mart.) ethanol fruit extract reverses alloxan-treatment alterations in experimental animals. *Mediterranean Journal of Nutrition and Metabolism*, 15, 429–445. DOI:10.3233/MNM-211589.
- Adams, M.D., Manu, H.A. and Enyioma-Alozie, S. (2025b). Molecular Docking, Contraceptive Property and Histopathological Changes in Experimental Models by *Digitaria exilis* Grain Extract via Interference with Steroidogenesis at Ovarian Level. *Tropical Journal of Natural Product Research*, 9(7), 3349 – 3359. <https://doi.org/10.26538/tjnpr/v9i7.63>.
- Adams, M.D., Muftaudeen T.K. and Saliu, O.A. (2023). Polyphenol-rich Extract of *Digitaria exilis* (Kippist) Grain Lowers Gastrointestinal Dysmotility and Enhanced Colonic Peristalsis in Rifaximin-induced Constipated Rat. *Nigerian Journal of Biochemistry and Molecular Biology*, 38(3), 131-138, 2023. DOI: <https://dx.doi.org/10.4314/njbmb.v38i3.4>.
- Adams, M.D., Okere, O.S., Tarfa, F.D. and Eze E.D. (2017). Toxicological evaluation of aqueous and methanolic leaf extract of *Cannabis sativa* in liver and brain of male rats. *European Journal of Biomedical and Pharmaceutical Sciences*, 4(8), 972-983.
- Adams, M.D. and Yakubu, M.T. (2020). Aqueous extract of *Digitaria exilis* grains ameliorate diabetes in streptozotocin-induced diabetic male Wistar rats. *Journal of Ethnopharmacology*, 249 (2020), 112383. <https://doi.org/10.1016/j.jep.2019.112383>.

- Adams, M.D. (2025a). *In Silico* Evaluation of Phytocompounds from *Digitaria exilis* Aqueous Grain Extract as Potential Inhibitors of  $\alpha$ -Amylase in Management of Type-II Diabetes Mellitus. *Dutse Journal of Pure and Applied Sciences*, 11(4b), 148-165. <https://dx.doi.org/10.4314/dujopas.v11i4b.14>.
- Agada, S.A., Odama, R.I., Kenechukwu, C.O., Aondoaseer, K., Ezech, C.O., Uti, D.E. and Alum, E.U. (2024). Antioxidant and hepatoprotective effects of methanolic seed extract of *Telfairia occidentalis* on carbon tetrachloride induced hepatic damage in Wistar rats. *Discover Medicine*, 1, 75. <https://doi.org/10.1007/s44337-024-00096-6>.
- Alkinani, K.B., Ali, E.M.M., Al-Shaikh, T.M., Awlia-Khan, J.A., Al-Naomasi, T.M., Ali, S.S., Abduljawad, A.A., Mosa, O.F. and Zafar, T.A. (2021). Hepatoprotective Effects of (-) Epicatechin in CCl<sub>4</sub>-induced toxicity model are mediated via modulation of oxidative stress markers in rats. *Evidence Based Complementary and Alternative Medicine*, 2021, e4655150. <https://doi.org/10.1155/2021/4655150>.
- Al-Nadaf, A.H., Shahin, N.A., Awadallaha, A., Obidat, R., Arman, S. and Thiab, S. (2025). An experimental investigation evaluating the protective effect of a hydroalcoholic extract of the aerial portion of Alenda (*Ephedra fragilis* Desf.) against hepatotoxicity caused by mercaptopurine in rats. *Journal of Applied Pharmaceutical Science*, 15(05), 223–231. <http://doi.org/10.7324/JAPS.2025.907107>.
- Al-Sheddi, E.S., Farshori1, N.N., Al-Oqail, M.M., Musarrat, J., Al-Khedhairi, A.A. and Siddiqui, M.A. (2015). Protective effect of *Lepidium sativum* seed extract against hydrogen peroxide-induced cytotoxicity and oxidative stress in human liver cells (HepG2). *Pharmaceutical Biology*, 1: 1-8. DOI: 10.3109/13880209.2015.1035795.
- Ayoub, S.S. (2021). Paracetamol (acetaminophen): A familiar drug with an unexplained mechanism of action. *Temperature*, 8(4), 351-371. <https://doi.org/10.1080/23328940.2021.1886392>.
- Babyvanitha, S., Vinothkumar, V. and Jaykar, B. (2023). Protective Role of Herbal Plants in Hepatotoxicity. *Global Journal of Health Sciences*, 8(1), 14–28. <https://doi.org/10.47604/gjhs.1761>.
- Balogou, V.Y., Soumanou, M.M., Toukourou, F. and Hounhouigan, J.D. (2013). Structure and nutritional composition of Fonio (*Digitaria exilis*) grains: a review. *International Research Journal of Biological Sciences*, 2(1), 73–79.
- Camera, E., Rinaldi, M., Briganti, S., Picardo, M. and Fanali, S. (2001). Simultaneous determination of reduced and oxidized glutathione in peripheral blood mononuclear cells by liquid chromatography–electrospray mass spectrometry. *Journal of Chromatography B: Biomedical Sciences and Applications*, 757(1), 69–78. [https://doi.org/10.1016/S0378347\(01\)00081-0](https://doi.org/10.1016/S0378347(01)00081-0).
- Cheng, J., Luo, M., Zhou, D.-D., Huang, S., Xiong, R., Wu, S., Saimaiti, A., Li, B., Shang, A., Tang, G.-Y. and Li, H. (2024). Effects of Several Tea-like Plants on Liver Injury Induced by Alcohol via Their Antioxidation, Anti-Inflammation, and Regulation of Gut Microbiota. *Foods*, 13(16), 2521. <https://doi.org/10.3390/foods13162521>.
- David, S. and Hamilton, J.P. (2010). Drug-induced Liver Injury. *US Gastroenterology and Hepatology Review*, 6, 73-80.
- de-Oliveira, F.K., Santos, L.O. and Garda-Buffon, J. (2021). Mechanism of action, sources, and application of peroxidases. *Food Research International*, 143(3), 110266. DOI:10.1016/j.foodres.2021.110266.
- Devarbhavi, H., Asrani, S.K., Arab, J.P., Nartey, Y.A., Pose, E. and Kamath, P.S. (2023). Global burden of liver disease: 2023 update. *Journal of Hepatology*, 79, 516–537. doi: 10.1016/j.jhep.2023.03.017.
- El-wessemy, A.M.M. (2008). Histopathological and ultra-structural studies on the side effects of the analgesic drug tramadol on the liver of albino mice. *Egyptian Journal of Zoology*, 50, 423-442.
- Fayazi, M. (2019). Determination of H<sub>2</sub>O<sub>2</sub> in Human Serum Samples with Novel

- Electrochemical Sensor Based on V<sub>2</sub>O<sub>5</sub>/VO<sub>2</sub> Nanostructures. *Annals of Military and Health Science Research*, 17(3), e96175. doi: 10.5812/amh.96175.
- Foghis, M. Bungau, S.G., Bungau, A.F., Vesa, C.M. Purza, A.L., Tarce, A.G., Tit, D.M., Pallag, A., Behl, T., Ul-Hassan, S.S. and Radu, A.F. (2023). Plants-based medicine implication in the evolution of chronic liver diseases. *Biomedicine and Pharmacotherapy*, 158: 114207. <https://doi.org/10.1016/j.biopha.2022.114207>.
- Gan, C., Yuan, Y., Shen, H., Gao, J., Kong, X., Che, Z., Guo Y., Wang, H., Dong, E. and Xiao J. (2025). Liver diseases: epidemiology, causes, trends and predictions. *Signal Transduction and Targeted Therapy*, 10(1), 33. <https://doi.org/10.1038/s41392-024-02072-z>.
- Garcia-Cortes, M. and Garcia-Garcia, A. (2022). Management of Pharmacologic Adverse Effects in Advanced Liver Disease. *Clinical Drug Investigation*, 42, 33–38. doi: 10.1007/s40261-022-01150-w.
- Gornall, A.C., Bardawill, C.J. and David, M.M. (1949). Determination of serum protein by means of Biuret reaction. *Journal of Biological Chemistry*, 177(2), 751–766.
- Hayden K. and Heyningen, C.V. (2001). Measurement of Total Protein Is a Useful Inclusion in Liver Function Test Profiles. *Clinical Chemistry*, 47(4) 793–794. <https://doi.org/10.1093/clinchem/47.4.793>.
- Hamza, T.A. and Hadwan, M.H. (2020). New spectrophotometric method for the assessment of catalase enzyme activity in biological tissues. *Current Analytical Chemistry*, 16(8), 1054–1062. DOI: 10.2174/1573411016666200116091238.
- Heuze, V., Tran, G., Hassoun, P. and Lebas, F. (2019). Fonio (*Digitaria exilis*) grain. Feedipedia, a programme by INRAE, CIRAD, AFZ and FAO. <https://feedipedia.org/node/228>. Last updated on August 30, 2019, 11:04.
- Innih, R.E., Bankole, J.K., Idehen, C.I., Asibor, E., Echekwube, M.E., Ogedegbe, A., Momodu, A., Iyevhobu, K.O., Oviosun, M., Okhun, E. and Eigbedion, A.O. (2025). Histomorphology Architecture and Weight Changes Following Long Term Exposure to Marijuana (Cannabis Sativa) Smoke on the Liver of Wistar Rats. *Journal of Advances in Medical and Pharmaceutical Sciences*, 27(7), 48–58. <https://doi.org/10.9734/jamps/2025/v27i7798>.
- Iroanya, O.O., Ekwuatu, T.F. and Chukwudozie, O. (2018). Hepatoprotective Effect of the Ethanolic Extract of *Jatropha tanjorensis* on Acetaminophen-Induced toxicity in Rat Model. *Journal of Biological Research and Biotechnology*, 16(1), 995-1001. <https://dx.doi.org/10.4314/br.v16i1.1>
- Jebese-Uduru, O.F., Elekima, I. and Obisike, U.A. (2025). Toxicological and Histopathological Analysis of Neem Leaf Extract and Edible Camphor on the Liver of Wistar Rats. *International Research Journal of Gastroenterology and Hepatology*, 8(1), 133–148. <https://doi.org/10.9734/irjgh/2025/v8i1121>.
- John, J.E., Tytler, B.A., Habila, J., Apeji, Y.E., Olayemi, O. and Isimi C.Y. (2022). Cross-linking with multifunctional excipients and its effect on the physicochemical properties and release profile of ibuprofen-loaded *Digitaria exilis* starch nanoparticles. *Journal of research in pharmacy (online)*, 26(5), 1190-1201. doi.org/10.29228/jrp.212.
- Kanioura, A., Geka, G., Kochylas, I., Likodimos, V., Gardelis, S., Dimitriou, A., Papanikolaou, N., Kakabakos, S. and Petrou, P. (2024). Superoxide Dismutase Detection on Silver Nanostructured Substrates through Surface-Enhanced Spectroscopic Techniques. *Chemosensors*, 12(6), 89. <https://doi.org/10.3390/chemosensors12060089>.
- Khudhair, D.A., Alkufaishi, Z. and Rashid, A.I. (2025). Dose-Dependent Histopathological and Biochemical Hepatotoxicity of Paracetamol in Rats: Dose-Dependent Paracetamol Hepatotoxicity in Rats. *Babcock University Medical Journal*, 8(1), 217–223.

- <https://doi.org/10.38029/babcockuniv.m.ed.j.v8i1.809>.
- Kim, Y., Kim, H. and Kim, Y. (2025). Advancing hepatotoxicity assessment: current advances and future directions. *Toxicological Research*, 41, 303–323. <https://doi.org/10.1007/s43188-025-00289-w>.
- Kodariah, L. Rezaldy, R. Kesuma, S. and Baehaki, F. (2022). Liver histology of Wistar rats (*Rattus norvegicus*) following oral administration of 50% ethanol. *Journal of Sustainability and Technology*, 2(1), 33-44. DOI: 10.23960/josst.v2i1.21.
- Mittal, G.A.P., Dhali, A., Prasad, R.S.Y., Nurani, K.M. and Gaman, M.A. (2025). Plant extracts with antioxidant and hepatoprotective benefits for liver health: A bibliometric analysis of drug delivery systems. *World Journal of Gastroenterology*, 31(18), 105836. doi: 10.3748/wjg.v31.i18.105836
- Neyrinck, A. (2004). Modulation of Kupffer cell activity: Physio-pathological consequences on hepatic metabolism. *Bull. Mem. Academic Research Medicine of Belgium*, 159(5-5), 358- 366.
- Nisar, J., Sarwar, M., Shah, S.A.R., Yasmin, S., Farooq, H., Moin, H. and Mustafa, I. (2025). *Lagerstroemia indica* methanolic extract alleviates CCl<sub>4</sub>-induced liver toxicity via modulation of Nrf2 signaling pathway in rats. *Asian Pacific Journal of Tropical Biomedicine*, 15(9), 374-383. DOI: 10.4103/apjtb.apjtb\_202\_25.
- Nweke, E.O., Ewa, O., Uche, E.M., Ibezim, E.O., Victor, C. A., Ubani, C.D. and Ude, U.T. (2025). Effect of ethanol extract of fonio millet on the hepatic health and body weight of diabetic rats. *Coast Journal of the School of Science*, 7 (1), 1123 – 1129. <https://dx.doi.org/10.4314/coast.v7i1>
- Ojo, O.A., Adeyemo, T.R., Iyobhebhe, M., Adams, M.D., Asaleye, R.M., Evbuomwan, I.O., Abdurrahman, J., Maduakolam-Aniobi, T.C., Nwonuma, C.O., Odesanmi, O.E. and Ojo, A.B. (2024). *Beta vulgaris* L. beetroot protects against iron-induced liver injury by restoring antioxidant pathways and regulating cellular functions. *Scientific Reports*, 14, 25205. <https://doi.org/10.1038/s41598-024-77503-6>.
- Okere, O.S., Adams, M.D., Ifeonu, S.C., Abioye, J.O.K., Abdullahi, D.K. and Adebayo, O.F. (2014). Toxicological Evaluation of Methanolic Leaf Extract of *Calotropis procera* (Ait.) R. Br. on Selected Biochemical Parameters in Rats. *The Journal of Toxicology and Health*, 105, 456-463.
- Olu-Owolabi, I.B., Olayinka, O.O., Adegbeemile, A.A. and Adebowale, K.O. (2014). Comparison of Functional Properties between Native and Chemically Modified Starches from Acha (*Digitaria* Stapf) Grains. *Food and Nutrition Sciences*, 5(2), 222-230. doi: 10.4236/fns.2014.52027.
- Qadri, S.S., Javaid, D., Reyaz, A., Ganie, S.Y. and Reshi, M.S. (2025). Liver disorders and phytotherapy. *Toxicology Reports*, 14, 102047. <https://doi.org/10.1016/j.toxrep.2025.102047>.
- Reitman, S. and Frankel, S. (1957). A colourimetric method for determination of serum glutamate-oxaloacetate and pyruvate transaminase. *American Journal of Clinical Pathology*, 28(1), 56–63. doi: 10.1093/ajcp/28.1.56.
- Rocha-Pereira, C., Silva, V., Costa, V.M., Silva, R., Garcia, J. and Goncalves-Monteiro, S. (2029). Histological and toxicological evaluation, in rat, of a P-glycoprotein inducer and activator: 1-(propan-2-ylamino)-4-propoxy-9H-thioxanthen-9-one (TX5). *Experimental and Clinical Sciences Journal (EXCLI Journal)*, 18, 697–722. doi: 10.17179/excli2019-1675.
- Roy, S., Shah, Z. and Chakraborty, G.S. (2024). A brief overview of drug-induced liver damage. *The Egyptian Journal of Internal Medicine*, 36 (56), 1-8. <https://doi.org/10.1186/s43162-024-00315-7>.
- Subramanya, S.B., Venkataraman, B., Meeran, M.F.N., Goyal, S.N., Patil, C.R. and Ojha, S. (2018). Therapeutic Potential of Plants and Plant Derived Phytochemicals against Acetaminophen-Induced Liver Injury. *International Journal of Molecular Sciences*. 19(12), 3776. <https://doi.org/10.3390/ijms19123776>



- Thakur, S., Kumar, V., Das, R., Sharma, V. and Mehta, D.K. (2024). Biomarkers of Hepatic Toxicity: An Overview. *Current Therapeutic Research*, 100 (100737).  
<https://doi.org/10.1016/j.curtheres.2024.100737>.
- Tiwari, V., Shandily, S., Albert, J., Mishra, V., Dikkatwar, M., Singh, R., Sah, S.K. and Chand, S. (2025). Insights into medication-induced liver injury: Understanding and management strategies. *Toxicology Report*, 14 (101976). doi: [10.1016/j.toxrep.2025.101976](https://doi.org/10.1016/j.toxrep.2025.101976).
- Trease, G.E. and Evans, W.C. (1983). A Textbook of Pharmacognosy, Twelfth ed. Bailliere-Tindall Ltd., London, pp. 343–383.
- Tsikas, D. (2017). Assessment of Lipid Peroxidation by Measuring Malondialdehyde (MDA) and Relatives in Biological Samples: Analytical and Biological Challenges. *Analytical Biochemistry*, 524, 13-30.  
<https://doi.org/10.1016/j.ab.2016.10.02>.
- Umerah, N.N. and Asouzu, A.I. (2023). Modulation of the Expression of Lipogenic Activity by Malted Hungry Rice Flour (*Digitaria exilis*) on Rats Induced with Obesity. *Asian Journal of Research in Biochemistry*, 12(3), 30-40.  
DOI: 10.9734/AJRB/2023/v12i3238.
- Wright, P.J., Leathwood, P.D. and Plummer, D.T. (1972). Enzymes in rat urine. Alkaline phosphatase. *Enzymologia*, 42(2), 317–327.
- Wu, X.N., Xue, F., Zhang, N., Zhang, W., Hou, J.J., Lv, Y., Xiang, J.X. and Zhang, X.F. (2024). Global burden of liver cirrhosis and other chronic liver diseases caused by specific etiologies from 1990 to 2019. *BMC Public Health*, 24, 1–15. <https://doi.org/10.1186/s12889-024-17948-6>.
- Zhou, Y., Wang, J., Zhang, D., Liu, J., Wu, Q., Chen, J., Tan, P., Xing, B., Han, Y., Zhang, P., Xiao, X. and Pei, J. (2021). Mechanism of drug-induced liver injury and hepatoprotective effects of natural drugs. *Chinese Medicine*, 16(1), 135. doi: 10.1186/s13020-021-00543-x.