



Research Article

Assessment of Hepatotoxic Effects and Serum Enzyme Changes Induced by *Naja melanoleuca* Venom in Albino Rats

Yahaya Tijani¹, Abubakar Shettima^{2*}, Maryam Saleh Bukar¹, Miriam Watafua¹, Babagana Modu¹, Bulama Burah¹, Baba Sale Madu¹, Afiniki Mhya Bitrus¹, Andrew Onu³ and Hassan Zanna¹

¹Department of Biochemistry, Faculty of Life Sciences, University of Maiduguri, PMB 1069, Maiduguri, Nigeria

²Department of Microbiology, Faculty of Life Sciences, University of Maiduguri, PMB 1069, Maiduguri, Nigeria

³Department of Biochemistry, Faculty of Clinical and Life Sciences, Usmanu Danfodi University

*Corresponding author's Email: abshettima@unimaid.edu.ng, doi.org/10.55639/607.504948

ARTICLE INFO:

ABSTRACT

Keywords:

LD₅₀,
Hepatotoxic,
Naja melanoleuca,
AST,
ALT

Snake envenoming is a crucial problem in west Africa and other parts of the world in which humans and animals are at risk. In this study the intravenous LD₅₀ of *Naja melanoleuca* venom was investigated using arithmetic method and the histopathological effect of *Naja melanoleuca* venom was investigated on the liver of albino mice. The serum enzymes Aspartate Transaminase, Alkaline Transaminase, Alkaline Phosphatase, Albumin and Total Protein levels of mice injected with *Naja melanoleuca* venom at different doses ((0.1mg/kg, 0.2mg/kg, 0.4mg/kg, 0.8mg/kg and 1.6mg/kg)) were also investigated spectrophotometrically. The intravenous LD₅₀ assessment of the venom was found to be 0.93mg/kg. The venom induces various cellular changes on the liver tissue, a typical hepatotoxic effect of *Naja* venom. There was a significant decrease in the AST and ALT level of the serum compared to the control. A significant increase of about 324.00U/L in the ALP level was observed upon injection of 1.6mg/kg of the venom compared to the control. Significant decrease in the ALB level upon injection of the lowest, medium and the highest venom dose was revealed, likewise a significant increase in the TP level upon administration of 1.6mg venom was observed compared to the control group injected with normal saline. Therefore, these findings are essential to elucidate the mechanism underlying the various cellular changes induced by *Naja melanoleuca* venom and antivenom development.

Corresponding author: Abubakar Shettima, **Email:** abshettima@unimaid.edu.ng
Department of Microbiology, Faculty of Life Sciences, University of Maiduguri, Nigeria

INTRODUCTION

Snakebite envenoming is a global medical problem especially in the rural areas of the tropics with about 81000 to 138000 deaths worldwide annually (Chippaux and Jackson 2019). The annual snakebite incidence in savannah region of Northern Nigeria has been estimated to be 497 per 100,000 populations with 12.2% mortality (Karaye *et al.*, 2012).

Forest cobra (*Naja melanoleuca*) commonly called the black cobra and white lipped cobra is specie of venomous snake that belongs to the family of elapidae (Burton 2002). The specie is native to Africa, mostly the central and western part of the continent (Mattison, 2007). It is the largest cobra species with a record length of 3.2 meters (10 feet 6 inches) (Chippaux and Jackson, 2019). Forest cobras prefer lowland forest and most savannah habitat, although it is highly adaptable and can be found in drier climates within its geographical region, it is considered a semi aquatic as it is a very capable swimmer (Shea 2005). Forest cobra feeds on large insect, mammals, and other reptiles. Forest cobra is one of the least frequent causes of snakebite among African cobras largely due to its forest dwelling habits but a bite by this species should be taken seriously because it is ranked as the 4th most venomous *Naja* (true cobra specie) (Spaws *et al.*, 1995).

Venom is defined as a secretion produced in a specialized gland of animal and delivered to a target animal through the infliction of a wound which contains molecules that disrupt normal physiological or biochemical processes to facilitate feeding or defense (Ernest, 2012). Venom is composed of proteins and peptide and has two primary functions; to paralyze their prey and start the digestive process with hydrolyzing proteins leading to necrosis and blood clotting (Vyas *et al.*, 2013). Cobra venom is composed of many different proteins including a variety of

enzymes proteases and phospholipases, non-enzymatic polypeptide toxins (neurotoxins and cardiotoxins) anti-coagulants (Lomonte and Jose 2012). It has acidic pH, specific gravity of 1.4 and is water soluble. Phosphodiesterase A2 causes hemolysis by lysing cell membrane of red blood cells. Oxidases and proteases are used for digestion. Snake venom contains inorganic cations such as sodium potassium magnesium and small amount of zinc, nickel, cobalt, iron (Sani *et al.*, 2018). Two major classifications of toxins found in snake venom include neurotoxins (those which affect nervous system) and cytotoxins which are those that attack cells (Omran *et al.*, 2004).

The liver as a vital organ responsible for detoxification, metabolism, and maintenance of energy balance and synthesis of various compounds is susceptible to damage from various external factors including venomous substances. Cobra venom leads to granular degeneration and accumulation of fat in the liver cells. The release of enzymes into the body circulation is mostly regarded as an indicator of damage in the hepatocyte (Kurfi *et al.*, 2021). The aim of this study was to determine the hepatotoxic effect of *Naja melanoleuca* venom on the liver of albino rats.

MATERIALS AND METHODS

Venom

Lyophilized forest cobra venom was obtained from the Department of Biochemistry University of Maiduguri, Maiduguri, Borno State, Nigeria. The venom was dissolved in PBS at a pH of 7.4 and was stored at 4°C.

Animal model

Wistar albino rats of different weight, age and gender were obtained from the Animal House, Department of Biochemistry University of Maiduguri. They were allowed to acclimatize for 14 days before the commencement of the experiment.

Study Design

Eighteen (18) rats were grouped into six (n^3). The rats were weighed and marked for identification. The first group was the control while the other five were the test groups. To the control group (group O), 0.5ml phosphate buffer saline was injected intravenously while the test group A, B, C, D and E received

0.1mg/kg, 0.2mg/kg, 0.4mg/kg, 0.8mg/kg and 1.6mg/kg venom dose. Irritability, collapse of diaphragm, paralysis, loss of appetite and confusion were all observed before sacrificing the animals. The rats were euthanized after 24 hours, and samples were collected. The LD₅₀ was estimated as shown in Table 1

Table 1: Intravenous LD₅₀ Estimation

Group	Dose (mg/kg)	Dose Difference (DD)	No. of Animals per group	No. of Dead	Mean Dead (MD)	DDxMD	LD ₅₀ (mg/kg)
1	CONTROL	-	3	0	0	0	
2	0.2	0.2	3	1.0	0.5	0.10	
3	0.4	0.2	3	2.0	1.5	0.30	
4	0.8	0.4	3	2.0	2.0	0.80	
5	1.6	0.8	3	2.0	2.0	1.60	
6	3.2	1.6	3	3.0	2.5	4.00	
Total						6.80	0.93

Sample Collection and Storage

Blood samples were collected in a plain container prior to the death of the animals.

The tissue samples were harvested and preserved in formalin.

Liver Tissue Gross Histopathological Examination

Histopathological examination was performed using liver tissue obtained from the experimental animals. The liver was preserved in 10% formalin for 48 hours and dehydrated in graded series of ethanol (95% to 100%). The liver tissue was cleared in xylene and embedded in paraffin section (4-5 micrometer) thick was prepared, stain with hemoxylin and eosin (H-E) dye for light

microscope observation using objective lenses. The image was snapped with digital camera for viewing.

Biochemical Analysis for Liver Function

Serum alanine aminotransferase (ALT), alkaline phosphates (ALP), ALK, TP and ALB were determined spectrophotometrically, as described by Reitman and Frankel (1965).

RESULTS

An intravenous LD₅₀ of 0.93mg/kg was obtained as shown in Table 2. This shows a lower potency than a previously reported LD50 values for other Naja species (Kazemi *et al.*, 2019; Wong *et al.*, 2019)

Table 2: Summary of Intravenous *Naja melanoleuca* venom LD₅₀

	Route Administration	of LD ₅₀ (mg/kg)	Value	Reference
<i>Naja melanoleuca</i>	Intravenous	0.93		Current study
<i>Naja oxiana</i>	Intravenous	0.21		Kazemi <i>et al.</i> , 2019
<i>Naja kaouthia</i>	Intravenous	0.30		Wong <i>et al.</i> , 2019

Figure 1 shows the liver tissue sections of the rat following venom administration.

Plate 1: Control group composed of portal tract (red arrow), central vein (Green arrow), hepatocyte (yellow arrow) and sinusoid (Blue arrow) that are unremarkable. Plate 2: Liver tissue injected with 0.1mg of *Naja melanoleuca* venom. Liver tissue composed of portal tract (Red arrow), central vein (yellow arrow), hepatocyte (blue arrow) and sinusoid (green arrow) that are normal. Plate 3: Liver tissue injected with 0.2mg of *Naja melanoleuca* venom. liver tissue showing thickening of sinusoid (blue arrow), the portal and central vein with mild inflammation (red arrow) and parenchyma like control, however there is marked congestion of the cytoplasm (red dots). Plate 4: Liver tissue injected with 0.4mg/kg *Naja melanoleuca* venom. Liver

tissue shows thickening of sinusoid (blue arrow), the portal and the central vein has mild inflammation and parenchyma red (arrow) similar to control. However, there is marked congestion of the cytoplasm (red dots). Plate 5: Liver tissue injected with 0.8mg/kg *Naja melanoleuca* venom. It shows inflammation of the periportal vein and chronic congestion (red arrow), there is vestibular steatosis in all the (zones; peripheral zone, intermediate zone & central zone) (yellow arrow) that composed hepatocytes (blue arrow) that are uniform. Plate 6: Liver tissue injected with 1.6 mg/kg *Naja melanoleuca* venom. It shows a liver tissue with marked expansion of the central vein (blue arrow). The portal tract (red arrow) has chronic inflammation and showing some focal necrosis.

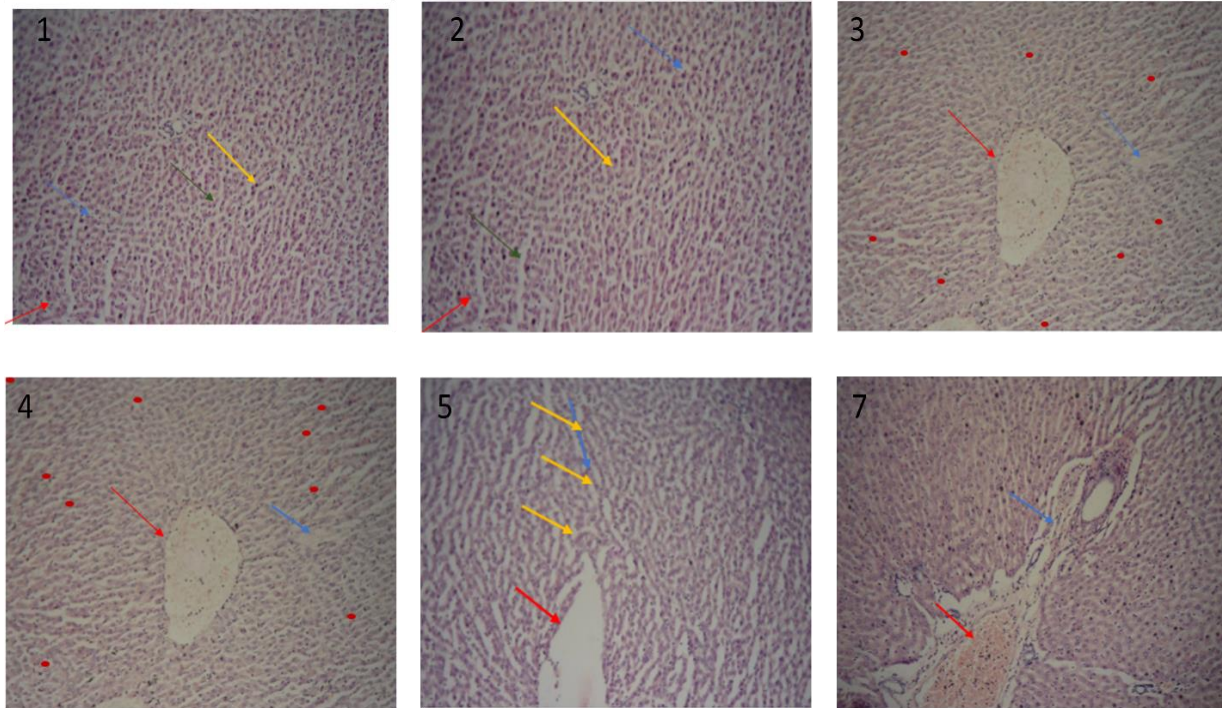


Figure 1: Photomicrograph of the liver tissue (at magnification x10).

Table 3 shows the liver enzymes after *Naja melanoleuca* venom administration. A significant increase in AST and TP values

were observed in the group administered with higher venom dose. The other parameters show a dose-dependent decrease.

Table 3: Liver Enzymes Level of albino rats Injected Intravenously with *Naja melanoleuca* venom

Parameter	Control (NS)	0.1mg/kg GROUP1	0.2mg/kg GROUP 2	0.4mg/kg GROUP 3	0.8mg/kg GROUP4	1.6mg/kg GROUP 5
AST (U/L)	116.667±7.22	71.334±14.723*	66.334±1.453*	80.0±8.186*	87.667±4.911	42.667±15.301*
ALT (U/L)	115.667±11.259	82.000±3.46*	75.667±2.404*	80.000±4.933*	88.000±0.577*	28.000±6.929*
ALK	167.000±34.934	158.667±36.085	103.000±1.528	103.666±0.881	150.667±26.847	324.000±128.172*
ALB	44.000±1.154	40.667±0.882*	44.000±1.155	43.667±1.202	38.334±0.882*	40.000±0.000*
TP	73.334±1.453	69.000±2.887	76.667±1.202	77.000±1.155	72.000±1.527	78.667±0.882*

Values were expressed as mean ±SEM (n=3), NS = Normal saline, G = Group

*Significant difference with the normal group (p<0.05)

Keys:

AST (Aspartate Transaminase) significant decrease (*) with Control group injected with Normal Saline.

ALT (Alanine Transaminase) significant decrease (*) with Control group.

ALK (Alkaline Phosphatase) significant increase (*) at Group 4 injected with 1.6mg/kg of venom.

ALB (Albumin) significant decrease at Group 1,4 and 5

TP (Total Protein) significant increase at Group 5

DISCUSSION

Snake envenomation is significant in Africa due to the presence of venomous snakes that can pose serious health risks (Pintar *et al.*, 2021). The region is home to various venomous species, and snakebites can lead to severe consequences, including tissue damage, organ failure, and even death. Limited access to medical facilities and antivenom in some areas further exacerbates the impact of snake envenomation in Africa. It is a critical health concern that requires attention and resources for effective prevention and treatment (Potet *et al.*, 2021). In this study, the intravenous *Naja melanoleuca* venom LD₅₀ was determined. It also explores the venom effects on liver tissue and liver biochemical parameters. This research can guide the development of targeted treatment and the development of specific anti-venom/anti-venom candidates against *Naja melanoleuca* venom.

The intravenous LD₅₀ was found to be 0.93mg/kg. Previous study of the same specie shows a higher value of 1.4mg/kg for subcutaneous administration (Yahaya *et al.*, 2023). A lower value of 0.324mg/kg for subcutaneous administration and value of 4.6mg/kg for intraperitoneal administration were also reported (Ernest *et al.*, 2022). These differences could be as a result of intra-specie (Jory *et al.*, 2023), regional (Fry *et al.*, 2003), age, sex and as a result of different mode of administration (Lidia *et al.*, 2022). For example, the bioavailability of venom is affected by the route of administration while sex, age and geographical distribution can affect the quality and toxins present in the venom (Amazonas *et al.*, 2018).

Inflammation of the liver is among the most common features of cobra snake envenoming (Adel *et al.*, 2023). In the present study Intravenous injection of *Naja melanoleuca*

venom induced dose-dependent histopathological changes. The changes include marked expansion of the central vein, chronic inflammation of portal tract, focal necrosis, inflammation of the periportal vein, chronic congestion, vestibular steatosis, marked congestion of cytoplasm, and mild inflammation of parenchyma. Similar changes were observed by (Adel *et al.*, 2009) in rat envenomed with another type of cobra, *Naja nigricolis*. These changes could be associated with various factors in cobra venom including cytotoxic effect of snake venom that directly damage liver cells. These cytotoxins (PLA₂s Phospholipases A₂, 3FTXs Three Finger toxins, SVMPS Snake venom metalloproteinases) disrupt the integrity of hepatocytes leading to cell death and subsequent release of cellular contents (Ferraz *et al.*, 2019). The release of intracellular molecules triggers inflammatory responses; attracting immune cells to the site of injury, this immune response contributes to the expansion of the central vein as a result of increased blood flow and vascular permeability (Kini, 2011). Venom phospholipase can also cause lysis of the membranous phospholipid after envenoming. This could cause the disturbance of cell membrane permeability of the liver cells and occurrence of the observed cytoplasmic changes (Tarek *et al.*, 2005). Focal necrosis could be due to the action of cobra cardiotoxin which show cytotoxicity toward several cell types (Tarek *et al.*, 2005). Vestibular steatosis is the accumulation of fat in the liver and this could be as a result of the disruption of the phospholipid cell membrane caused by venom phospholipase (Nanayakkara *et al.*, 2009).

AST and ALT are important biomarkers for cellular damages in the liver (Abdulrahman *et al.*, 2015). These enzymes are standard biochemical markers for assessing and

monitoring liver inflammation and necrosis. During inflammation, they are released into circulatory system due to increase permeability of the cell membrane or disruption of cells (Abdel *et al.*, 2009). There was significant decrease in AST and ALT level upon injection of low and high dose of *Naja melanoleuca* venom, other species of *Naja nigricolis* and *Bitis ariten* venom show increase in the liver enzymes, this could be as a result of different mode of administration or different species (Kurfi *et al.*, 2021). There is a decrease in ALK level upon administration of low dose but not at statistically significant level. However, administration of high dose of 1.6mg/kg of the venom results in increase in ALK level of about 324U/L which could be indicative of liver damage (Agrawal and Gupta, 2013). There is a significant decrease

CONCLUSION

Forest cobra envenomation can have severe effects on the liver, resulted in cellular damages and changes such as focal necrosis, congestion of cytoplasm, inflammation of parenchyma, vestibular steatosis etc. The venom also resulted in decrease in the aspartate transaminase, alkaline transaminase,

in serum albumin at 0.1mg/kg, 0.8mg/kg and 1.6mg/kg doses. However, significant increase in the total protein level at 1.6mg/kg doses was observed which can also indicate liver damage. This could be due to dehydration as a result of inappetence (Asyura *et al.*, 2016). ALT is the most sensitive and reliable enzyme for the assessment of liver function test, in this study there was a decrease in the ALT level, and this could be explained by the glucose alanine cycle in which pyruvate produced from glucose is transaminated to alanine via ALT enzyme and transported to the liver to be reconverted to glucose by gluconeogenesis to enhance the hyperglycemic phenomenon observed after envenomation (Kurfi *et al.*, 2021).

and albumin levels but there was a significant increase in alkaline phosphate and total protein level. This finding of the decrease in the AST and ALT level may be associated to the venom inflammatory properties or its interactions with specific liver enzymes however more research is required to fully understand the mechanism involved.

REFERENCES

- Abdel-Moneim A.E., M.A. Dkhil., and Al-Quraishy S. (2010). The redox status in rats treated with flaxseed oil and lead-induced hepatotoxicity Biol. Trace Elem. Res, 143 (1)457–467
- Abdulrahman, K. A., Haseeb A.K., Faisal A.B., Ahmad, A.B. & Rajamohammed, AM. (2015). Serum biomarkers for acute hepatotoxicity of *Echis pyramidum* snake venom in rats. International Journal of Clinical and Experimental Medicine(1):1379-1380.
- Adzu, B., Abubakar, M.S., Izebe, K.S., Akumka, D.D.& Gamaniel, K.S., (2005). Effect of *Annona senegalensis* root bark extracts on venom in rats. J. Ethnopharmacol. 96 (3), 507–513.
- Agrawal and Deepika Gupta (2013)."Assessment of liver damage in male Albino rats after repetitive heat stress of moderate levels" Journal of Physiology, vol 3 issue 2 p 147-152
- Amazonas D.R.,Jose A.P., Milton M.C., Rosa H.V., Felip G.G.,Milton Y.N.,Carolina A.N.,Hipocrates M.C.,Darin R.R., Gibbs H.L.,Richard H.V., Inacio L.M., & Junquiera A.(2018) "Molecular mechanism underlying intraspecific variation in

- snake venom." Journal of Proteomics 181 60-72
- Balde M.C., Chippaux J.P., Boiro M.Y., Stock R.P., and Massougboji A. (2013). Use of antivenoms for the treatment of envenomation by Elapidae snakes in Guinea, Sub-Saharan Africa. *The Journal of Venomous Animals and Toxins Including Tropical Diseases*, 19(1), 6.
- Bryan G.F., Kenneth D W.,Janith C.W.,Wayne C.H &Wolfgang W (2003).*Journal of Toxicology. Toxins review. Vol 22 (1) pp 23-34*
- Burton M, (2002)."International wide life encyclopedia" United State Marshal Cavendish corp,3rd edition Pp 481-482
- Chippaux J.P and Jackson K .(2019) "Snakes of central and western Africa (1st edition).John Hopkins University Press P.128 ISBN978-1421427195
- Ernest Hodgson (2012) " Toxins and venom " *Progress in Molecular Biology and Translational Science V 112 P373-415*
- Ernest Z. M., Mutinda C.K., Joseph K.G., Josephine K., and James H.K .(2022). Evaluation of lethality and cytotoxic effects induced by *Naja ashei* (large brown spitting cobra) venom and the envenomation-neutralizing efficacy of selected commercial antivenoms in Kenya, *Toxicon: X, Volume 14, 100125.*
- Ferraz C.R.,Arif A.,Chinfang X.,Nicholas R.C.,Richard J.L.,Jeroen K.,and Ferranda C. C. (2019) "Multifunctional Toxins in snake venom and therapeutic implications: From pain to Haemorrhage and necrosis".*Frontiers In Ecology and Evolution vol.7 article 218.*
- Gasanov S.E., Al-sarraj M.A., Gasanov N.E and Real E.D. (1997)" Cobra venom cytotoxin free of phospholipase A2 and Its effects on model membranes and T leukemia cells"*J Venom Anima Toxins incl Trop Dis. (15) (1):61-78.*
- Jory V.T., Luis L.A., Julien S., Nathan D., Roel M.W, Cassandra M.M., Freek J.V., Timothy N.W.,and Jeroen K. (2023). Highly Evolvable: Investigating Interspecific and Intraspecific Venom Variation in Taipans (*Oxyuranus spp.*) and Brown Snakes (*Pseudonaja spp.*). *Toxins*, 15(1), 74.
- Karaye, K.M.,Mijinyawa M.S.,Yakasai,A.M., Kwaghe V.,Joseph G.A.,and Iliyasu G.(2012) "Cardiac and hemodynamic features following snakebite in Nigeria. *Int J Cardiol 156 (3):326-328*
- Kazemi-Lomedasht, F., Yamabhai, M., Sabatier, J., Behdani, M., Zareinejad, M.R. and Shahbazzadeh, D. (2019). "Development of a human scFv antibody targeting the lethal Iranian cobra (Naja oxiana) snake venom". Toxicon. 171: 78–85.*
- Kini RM (2011)." Venom proteins: structure, function, and pharmacology". *Wiley Interdiscip Rev Syst Biol Med. ;3(3):355-366.*
- Kurfi B. G.,Ibrahim H.M., and Abdulazeez A. M (2021) "Histopathological studies on effects of serum enzymes of *Naja nigricolis* and *Bitis arietan* venom " *Science World Journal vol .16 (No 4)*
- Lidia J.F.,Daniel M.H.,Weslei S.A.,Eduardo O.V.,Jackson G.M., Alexandre K.T.,Savio S.S.,Kathleen F.G.,Karen D.M., and Anita M.T.(2022) ."Analyzing the influence of Age and Sex in Bothrops pauloensis snake venom" *Toxicon 214 78-90*
- Line P.L.,Andreas H.L.,Brono .L,Jose M .G,(2017). "Exploring the venom of the forest cobra snake" *Toxicovenomics and antivenom profiling of Naja melanoleuca" Journal of Proteomics (150),98-108*
- Lomonte B, and Jose R,(2012). "Snake Venom Lys49 Mytotoxins from phospholipases A2 to Non-enzymatic Membrane Disruptors." *Toxicon 60 (4), 520-530*

- Lougin M., Abdel Ghani.,Mohammed F., Osama A.A., and Tarek R.R.(2009). "Histological and Immunohistochemical studies on the hepatotoxic effects of the venom of *naja nigricolis* on albino mice".Egyptian Journal of Natural Toxins Vol 6(2):100-119.
- Mattison C, (2007) "The new encyclopedia of Snakes".New York Aly Press p 272.ISBN 978-0691-13295-2
- Nanayakkara D.P.,Ratnayake R.M., & Shirani J.G "Histopathological changes in brain, kidney and liver of mice following intramuscular administration of Krait venom". Cey.J.Sci (Bio.Science 38 (1): 1-10 of clinical and experimental Medicine, (1): 1379-1380.
- Omran M.A.,A S.A., & Fabb G. D. (2004) "Biochemical and Morphological analysis of cell death induced by egyptian Cobra (*Naja haje*) venom on cultured cells.
- Pintor AF, Ray N, Longbottom J, Bravo-Vega CA, Yousefi M, Murray KA, Ediriweera DS, Diggle PJ. Addressing the global snakebite crisis with geo-spatial analyses–Recent advances and future direction. Toxicon: X. 2021 Sep 1;11:100076
- Potet J, Beran D, Ray N, Alcoba G, Habib AG, Iliyasa G, Waldmann B, Ralph R, Faiz MA, Monteiro WM, Sachett JD. Access to antivenoms in the developing world: A multidisciplinary analysis. Toxicon: X. 2021 Nov 1;12:100086.
- Russell J.J., Schoenbrunner A., and Janis J.E. (2021)Snake Bite Management: A Scoping Review of the Literature. Plast Reconstr Surg Glob Open. 2021 Apr 29;9(4):e3506.
- Sajjaratul N.,Nadia A.,Hazilawati H.,Rosly M.S.,Shanmugavelu S., and Noordin M. M (2016) "Blood profiles and histopathological changes of liver and kidney tissues from male sprague Dawley Rats treated with ethanol extracts of *clinacanthus nutants* leaf. Journal of Clinical Toxicology vol. 6:329
- Sani. I, Umar R.A., Hassan S.W., Faruk U.Z.(2018). "Antisnake Venoms and their Mechanism of Action'. Vol 4 iss5 512-520
- Shea M (2005) ."venomous snakes of the world".UK New Holland publishers P71 ISBN0-691-12436-1
- Spawls.,Stephen .,&Branch .B(1995). "The Dangerous snakes of Africa (Revised Edition)" Ralph antis P.73 ISBN 978-0-88359-029-4
- Tarek R.,Rahmy M.,Mostafa H.,El-Naggar .,and Amir E (2005)."Immunohistochemical detection of hepatic injury after cobra snake envenoming" Egyptian Journal of Natural Toxins,vol.2., 119-134
- Vyas V.F.,Brahmbhatt K.,Bhat H., and Parmar U. (2013) "Therapeutic potential of snake venom in cancer therapy. Current Perspective Asian pacific Journal of Tropical Biomedicine V 3:156-162
- Wong, K.Y., Tan, C.H. and Tan, N.H. (2019). "Venom and Purified Toxins of the Spectacled Cobra (*Naja naja*) from Pakistan: Insights into Toxicity and Antivenom Neutralization". *The American Journal of Tropical Medicine and Hygiene.* 94 (6): 1392–1399.
- Yahaya Tijani, Sani Muhammad Uzairu, Afiniki Bitrus Mhya, Anas Aliyu Muhammm, Babagana Modu, Miriam watafua, Madu Adamu Gadaka, Suleiman Ali, Rabiun Shehu Sa'ad, Zakari Abba Ali, Goni Chamba, Abba Dige Abdulrahman Ali Ali and Hassan Zanna. (2023). "Forest Cobra (*Naja melanoleuca*) of Funtua, Katsina State Nigeria: Venom effect on Oxidative Stress" Journal of Pharmaceutical and Biomedical Research, volume 7 Issue 1